

Cryptococcal meningitis

Lillian Tugume¹✉, Kenneth Ssebambulidde^{1,2}, John Kasibante¹, Jayne Ellis^{1,3}, Rachel M. Wake⁴, Jane Gakuru¹, David S. Lawrence^{1,3,5}, Mahsa Abassi⁶, Radha Rajasingham⁶, David B. Meya^{1,6,7} & David R. Boulware^{1,6,7}

Abstract

Cryptococcus neoformans and *Cryptococcus gattii* species complexes cause meningoencephalitis with high fatality rates and considerable morbidity, particularly in persons with deficient T cell-mediated immunity, most commonly affecting people living with HIV. Whereas the global incidence of HIV-associated cryptococcal meningitis (HIV-CM) has decreased over the past decade, cryptococcosis still accounts for one in five AIDS-related deaths globally due to the persistent burden of advanced HIV disease. Moreover, mortality remains high (~50%) in low-resource settings. The armamentarium to decrease cryptococcosis-associated mortality is expanding: cryptococcal antigen screening in the serum and pre-emptive azole therapy for cryptococcal antigenaemia are well established, whereas enhanced pre-emptive combination treatment regimens to improve survival of persons with cryptococcal antigenaemia are in clinical trials. Short courses (≤ 7 days) of amphotericin-based therapy combined with flucytosine are currently the preferred options for induction therapy of cryptococcal meningitis. Whether short-course induction regimens improve long-term morbidity such as depression, reduced neurocognitive performance and physical disability among survivors is the subject of further study. Here, we discuss underlying immunology, changing epidemiology, and updates on the management of cryptococcal meningitis with emphasis on HIV-associated disease.

Sections

[Introduction](#)[Epidemiology](#)[Mechanisms/pathophysiology](#)[Diagnosis, screening and prevention](#)[Management](#)[Quality of life](#)[Outlook](#)

¹Infectious Diseases Institute, Makerere University, Kampala, Uganda. ²Laboratory of Clinical Immunology and Microbiology, National Institute of Allergy and Infectious Diseases, National Institutes of Health, Bethesda, MD, USA. ³Clinical Research Department, Faculty of Infectious and Tropical Diseases London School of Hygiene and Tropical Medicine, London, UK. ⁴Institute for Infection and Immunity, St George's University of London, London, UK. ⁵Botswana Harvard AIDS Institute Partnership, Gaborone, Botswana. ⁶Department of Medicine, University of Minnesota, Minneapolis, MN, USA. ⁷These authors contributed equally: David B. Meya, David R. Boulware.

✉e-mail: ltugume@idi.co.ug

Introduction

Cryptococcal meningitis is an opportunistic mycosis caused by invasion of *Cryptococcus* into the central nervous system (CNS), and most commonly occurs in individuals with advanced HIV disease (AHD). Less commonly, cryptococcal meningitis may occur in individuals with non-HIV-associated immunosuppression, or in apparently immunocompetent hosts^{1–3}, and the incidence of non-HIV-associated disease is increasing in high-income countries. Cryptococci are ubiquitous encapsulated yeasts of the phylum Basidiomycota and consist of several species. *Cryptococcus neoformans* and *Cryptococcus gattii* species complexes are known to cause disease in humans^{4,5}. *C. neoformans* typically causes fatal meningoencephalitis, especially among immunocompromised hosts. *C. gattii* is more likely to cause meningitis in apparently immunocompetent hosts except for cases in Southeast Asia where *C. neoformans* species predominate^{2,6}. Disease phenotypes are underpinned by complex host–yeast interactions.

Cryptococcal meningitis accounts for 15–20% of AIDS-associated deaths globally⁷. Nearly two-thirds of all deaths from HIV-associated cryptococcal meningitis (HIV–CM) occur in Africa, and 10-week mortality is as high as 50% of the incident cases in routine care settings⁸.

Current therapeutic protocols include the use of a combination of antifungal drugs, including amphotericin B, flucytosine and fluconazole. The polyene amphotericin B binds to ergosterol in the cytoplasmic membrane of fungi, causing the extravasation of intracellular electrolytes, carbohydrates and proteins, and is an essential anti-cryptococcal drug owing to its low resistance rate and potent fungicidal activity⁹. 5-Fluorouracil, a flucytosine derivative, inhibits fungal protein synthesis¹⁰. Owing to the rapid development of resistance, flucytosine monotherapy is not recommended. Both a fungistatic action through inhibition of ergosterol synthesis and a fungicidal activity associated with dose-dependent apoptotic responses have been described for fluconazole¹¹.

Poor treatment outcomes in routine settings have been partly attributed to life-threatening toxicities associated with 14-day courses of amphotericin-based induction therapy. Based on two multicentre landmark trials conducted in Africa during the period 2013–2022 (refs. 12,13), abbreviated courses (≤ 7 days) of amphotericin are now recommended by the World Health Organization (WHO), and these short regimens successfully reduce case fatality to ~25% in the clinical trial context. As treatment outcomes have improved over time, screening and prevention strategies have advanced in parallel. Cryptococcal meningitis is preceded by the detection of cryptococcal antigen (CrAg) in blood, and CrAg screening, followed by pre-emptive fluconazole therapy in cases of cryptococcal antigenemia with no CNS involvement, is life-saving and cost-effective for patients with AHD¹⁴.

In this Primer, we discuss updates on the epidemiology, immunology, diagnosis, management and prevention of cryptococcal meningitis, with emphasis on HIV–CM. We additionally discuss prospects for improving survival.

Epidemiology

The molecular age of taxonomy for cryptococci has enabled identification of strains by species complex, species, serotype, molecular type or lineage, and sequence type. *C. neoformans* and *C. gattii* species complexes are globally distributed, although *C. neoformans* is approximately eightfold to ninefold more frequently isolated than *C. gattii*¹⁵. Five major genetically distinct lineages of *C. neoformans* (VNI, VNII, VNIII, VNIV and VNB) and six of *C. gattii* (VGI, VGII, VGIII, VGIV, VGIV/GVIIIc and VGV) can be identified by multi-locus sequence typing¹⁶.

This is not inclusive of the *C. neoformans*–*C. gattii* hybrid genotypes. Of the 11 molecular types, VNI is the most prevalent worldwide, except in Australia and Papua New Guinea, where *C. gattii* is more prevalent¹⁵. The proportion of *C. gattii* is relatively lower in African and European isolates than in Asia and the Americas, and is endemic in Australia¹⁷. *C. gattii* was initially thought to be ecologically restricted to tropical and subtropical regions but this was disproved by the 1999 outbreak in temperate regions across North America¹⁸. Distribution of *C. gattii* lineages varies by region; for instance, VGII is the most common *C. gattii* lineage in the Americas and is linked to the 1999 outbreak in North America, which is thought to have originated from South America^{18,19}. VGI is the most common lineage in Europe, Asia and Australia, whereas VGII and VGIII are the most prevalent in the Americas. VGIV is the most common lineage in southern African isolates, and seems to have a predilection for immunocompromised hosts including those with HIV-associated disease¹⁷. Whether this distribution of *C. gattii* lineages is primarily a result of importation of pathogens from endemic areas is unclear because travel data are not consistently available. Molecular epidemiological data must be interpreted with caution because of sampling bias; for instance, Asia is over-represented in published multi-locus sequencing data and only a subset (approximately <15%) of isolates globally have been molecularly typed¹⁵. Additionally, over 80% of the published isolates are clinical isolates, which represent only a subset of the diversity in the environment¹⁵. Robust environmental genomic surveillance is useful for defining the risk of exposure to *Cryptococcus* and may partially explain patterns of disease.

HIV-associated cryptococcal meningitis

The global incidence of HIV–CM has generally decreased over the past decade but cryptococcal meningitis still accounts for an estimated 19% of all AIDS-related mortality^{7,20}. This global decline is due to improved access to antiretroviral therapy (ART), and increased CrAg screening and subsequent pre-emptive antifungal therapy. In Africa, the HIV–CM burden remains the highest globally, representing more than half of all incident HIV–CM cases in 2020, followed by the HIV–CM burden in the Asia and Pacific regions⁷ (Fig. 1). Historically, HIV–CM occurred predominantly in ART-naïve individuals who presented to care for the first time with AHD. Currently, and as a result of improved access to ART, more than half of individuals diagnosed with HIV–CM have had prior exposure to ART at the time of diagnosis^{21–23}. Generally, survival in patients with HIV–CM is not associated with ART status, except for those in whom ART unmasks the infection^{24,25}. A Ugandan study reported a twofold increase in the hazard of death when ART was initiated sooner than 2 weeks before cryptococcal diagnosis²⁶.

The incidence of cryptococcal antigenaemia among people living with HIV globally is 6.5% when CD4⁺ T cell counts are ≤ 100 cells/ μ l and approximately 2.0% when CD4⁺ T cell counts are in the range 101–200 cells/ μ l (refs. 7,20,27). Evidence that cryptococcal antigenaemia precedes cryptococcal meningitis if untreated was mainly derived from retrospective studies. A study in 707 patients on initial ART in South Africa demonstrated that baseline cryptococcal antigenaemia could predict the development of subsequent cryptococcal meningitis within a year with 100% sensitivity and 96% specificity²⁸. Testing of biobanked samples from a Ugandan cohort of patients who subsequently developed cryptococcal meningitis found that detectable CrAg in blood preceded meningitis symptoms by a median of 22 days (range 5–234 days)²⁹.

A complication of immune system recovery with ART after cryptococcosis is a paradoxical reaction. In HIV, this is termed paradoxical immune reconstitution inflammatory syndrome (IRIS). Over the

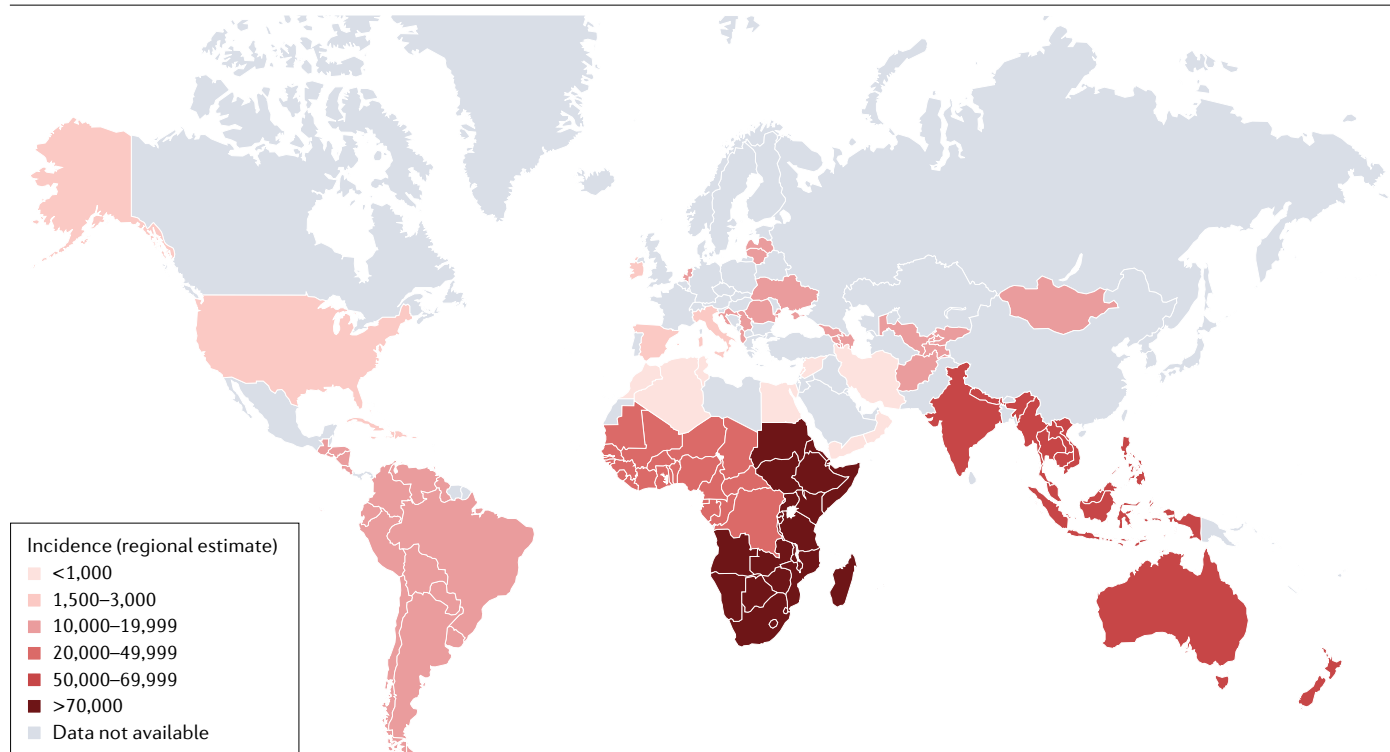


Fig. 1 | Global map of estimated incidence of HIV-associated cryptococcal meningitis in 2020. Regional estimates of incidence of HIV-associated cryptococcal meningitis (HIV–CM) incidence are based on UNAIDS estimates of the number of people living with HIV in the years 2019–2020, and the number of individuals with HIV at risk of cryptococcosis (that is, with a CD4⁺ T cell count of <200 cells/μl), and on the prevalence of cryptococcal antigenaemia in those with a CD4⁺ T cell count of <200 cells/μl by country and by region based on the

published literature. The number of cryptococcal antigen (CrAg)-positive people in each country and region was then estimated by multiplying the number of individuals at risk of cryptococcal infection by the prevalence of cryptococcal antigenaemia. Progression from cryptococcal antigenaemia to meningitis was then estimated based on the published literature⁷. Regional incidence data are based on the estimates provided in ref. 7.

past two decades, the incidence of cryptococcal IRIS has generally decreased from approximately 30% during the period 2003–2008 (refs. 30–33), to 3–20% during the period 2014–2022 (refs. 13,34–36), probably owing to the improvement in antifungal therapy combinations and the recommendation for delayed ART initiation. The median duration between ART initiation and the incidence of IRIS remains 4–8 weeks³⁷, while mortality following cryptococcal IRIS is 8–30%³⁸.

While the global incidence of HIV–CM has generally decreased, most recent global estimates indicate that the case fatality rate probably exceeds 50% outside clinical trials. There were approximately 152,000 new HIV–CM diagnoses in 2020 resulting in approximately 112,000 deaths, with two-thirds of the reported deaths occurring in Africa⁷. Cryptococcal related mortality is highest during the first 12 weeks following diagnosis^{34,39,40}. Under routine care conditions, 10-week mortality ranges from 19–50% in low-income and middle-income countries (LMICs) to less than 20% in high-income countries^{8,41–45}. Prognosis in clinical trials conducted in LMICs has improved in the past several years (10-week mortality of 24–36%)^{12,13}.

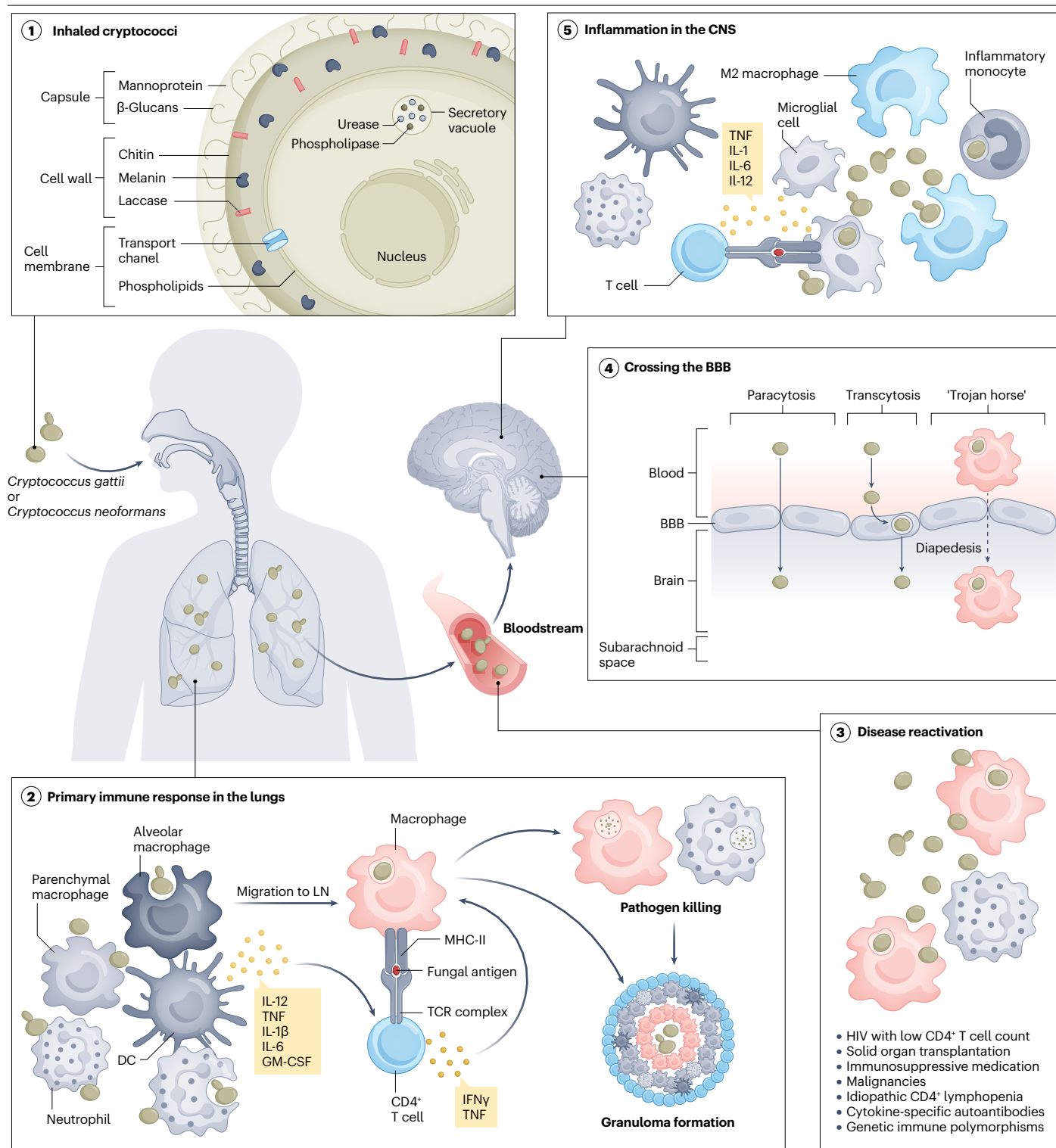
Despite pre-emptive antifungal therapy, cryptococcal antigenaemia remains a risk factor for death in patients with AHD. In prospective studies using pre-emptive fluconazole treatment, subsequent diagnoses of clinical cryptococcal meningitis are rare^{46–48}. However, patients with AHD and cryptococcal antigenaemia have a twofold to

threefold higher risk of death within 6 months than patients with AHD and equally low CD4⁺ T cell counts but CrAg-negative blood tests^{46–48}. This persistent excess mortality is most pronounced in individuals with high CrAg titres. Individuals with serum or plasma CrAg titres of ≥1:160 are three times more likely to die than those with CrAg titres ≤1:80 despite receiving fluconazole⁴⁹. The increased mortality risk suggests that fluconazole monotherapy is a suboptimal antifungal treatment for those with a high disseminated burden of infection, reflected by high CrAg titres in blood.

The strongest predictors of acute cryptococcal mortality under amphotericin-based induction therapy are the presence of altered mental state and high fungal burden at diagnosis³⁹. Moreover, the rate of fungal clearance from cerebrospinal fluid (CSF) is inversely associated with all-cause mortality^{50,51}. Thus, in the acute setting, the strategy of improving survival has been largely focused on maximizing clearance of the fungus with the most efficacious and safe antifungal regimens^{12,13}. To the contrary, improving outcomes by additionally targeting altered mental state in HIV–CM is more challenging as the pathogenesis is only partially understood.

Non-HIV cryptococcal meningitis

The global epidemiology of non-HIV–CM is not well described, but disease incidence is generally increasing in high-income countries in



association with an increase in the use of immunosuppressive therapies and an expansion in multi-morbid, ageing populations⁵². Risk factors among HIV-negative individuals include solid organ transplantation, autoimmune diseases, haematological malignancies, diabetes mellitus, chronic kidney and liver diseases, use of corticosteroids and

other immunosuppressive drugs, and alcoholism⁵³. The presence of granulocyte-macrophage colony-stimulating factor (GM-CSF)-specific autoantibodies and idiopathic CD4⁺ lymphocytopenia has been demonstrated on further immunological testing in some individuals with non-HIV-CM^{54–57}.

Fig. 2 | Host response to *Cryptococcus neoformans* infection. Infection with cryptococci occurs following inhalation into the lung (1). Several cryptococcal virulence factors, including the polysaccharide capsule, cell wall components (such as chitin and melanin), and the cryptococcal enzymes laccase, urease and phospholipase, contribute to immune evasion (1). In the lungs, yeast cells are phagocytosed by lung-resident macrophages and dendritic cells (DCs), which prime T cells, while also producing cytokines, such as tumour necrosis factor (TNF), granulocyte-macrophage colony-stimulating factor (GM-CSF), IL-1 β , IL-6 and IL-12 to favour a CD4⁺ T helper 1 (T_H1) phenotype. CD4⁺ T_H1 T cells enhance the killing capacity of macrophages by secreting interferon- γ (IFN γ) and TNF. In healthy individuals, the primary immune response results in clearance of the

fungi by phagocytes, or in formation of granulomas that contain the pathogens (2). Immunosuppression compromises granuloma integrity (3), leading to fungal dissemination via the bloodstream. Cryptococci cross the blood–brain barrier (BBB) at the subarachnoid space via paracytosis, transcytosis or the ‘Trojan horse’ mechanism, which involves monocytes or macrophages that carry phagocytosed cryptococci into the brain (4). Inflammation in the central nervous system (CNS) is characterized by mobilization of innate immune cells including microglial cells, monocytes and alternatively activated macrophages (M2), as well as by priming of T cells, which produce pro-inflammatory cytokines (5). LN, lymph node; MHC-II, MHC class II; TCR, T cell receptor.

In the USA, approximately 20% of patients with non-HIV–CM have no identifiable underlying immunosuppressive condition, and this proportion is higher in Asia (75–80%)^{1–3}. Whether this discrepancy is attributable to an unidentified immune deficit, increased genetic susceptibility in the host, or increased pathogenicity of *Cryptococcus* species is unclear. Some host factors have been partially associated with susceptibility of apparently immunocompetent individuals to cryptococcal meningitis, including a specific HLA class II allele (DQB1*05:02), or late-onset immunodeficiency syndrome associated with the production of interferon- γ (IFN γ)-specific autoantibodies^{58–60}. The likelihood of unidentified idiopathic CD4⁺ lymphocytopenia in the studied apparently immunocompetent patients with non-HIV–CM is low, as immunological testing was conducted.

Infection with *C. gattii* (especially with the VG1 or VGII *C. gattii* lineages) is more common in apparently immunocompetent individuals, whereas *C. neoformans* is the predominant species in immunocompromised individuals with cryptococcal meningitis^{6,61}. Paradoxically, *C. neoformans* species complex sequence type 5 (ST 5) is the dominant species isolated from apparently immunocompetent individuals in China and Vietnam^{2,3,62}. In vitro studies from a Vietnam cohort suggest that the ability to infect apparently immunocompetent hosts is related to an evolutionary advantage of *C. neoformans* ST 5 as evidenced by high phenotypic variation⁶³. Further, the presence of GM-CSF-specific autoantibodies in apparently immunocompetent patients with cryptococcal meningitis is presumably rare and commonly associated with *C. gattii*^{64–66}.

Studies from the USA and Taiwan from years 1990–2015 suggested that in-hospital mortality from cryptococcal meningitis is slightly higher among HIV-negative individuals than among those living with HIV^{67,68}. Delayed diagnosis contributes to this excess mortality, which stems from a low index of suspicion among HIV-negative individuals^{40,67}. Whether the specific underlying immune-compromising condition impacts survival is non-conclusive, as absolute numbers of patients are too few to study this robustly^{1,69}. Presently, any potential heterogeneity in immune status is not factored into the therapy of non-HIV–CM. Overall, susceptibility to cryptococcal meningitis, disease severity and clinical outcomes are associated with complex yeast–host interactions, and an advanced understanding of this relationship may enhance current prevention and treatment strategies.

Mechanisms/pathophysiology

C. neoformans is a ubiquitous basidiomycetous fungus isolatable from avian and non-avian sources⁷⁰. *C. gattii* has been isolated from the soil, air, water and several tree species, especially eucalypts^{71–73}. Immunopathogenesis of *C. neoformans* infections has been more intensively studied than that of *C. gattii* infections; therefore, the following sections

focus on disease mechanisms identified in studies of *C. neoformans*. Overall, *C. gattii* and *C. neoformans* express the same major virulence determinants.

Primary infection

C. neoformans infects individuals after they have inhaled desiccated yeast cells or infectious propagules called basidiospores into the lungs⁷⁴ (Fig. 2). Simultaneous or consecutive inhalation of multiple *C. neoformans* strains may result in mixed infections, with hosts testing positive for multiple yeast genotypes⁷⁵. The primary immune response that is initiated in the lungs may successfully clear the fungi. Any uncleared fungi are walled off and contained in granulomas, establishing a latent infection in immunocompetent hosts. In some individuals, immunosuppression leads to reactivation of the latent infection and distant haematogenous spread⁷⁶. Epidemiological studies have suggested that cryptococcal meningitis may occur in solid organ transplant recipients with no preceding latent stage^{77,78}.

Immune response to the primary infection

Alveolar macrophages and dendritic cells are the first responders to primary lung infection with cryptococci⁷⁹. The fungus is recognized by pattern recognition receptors including, C-type lectin receptors, dectin 1, mannose receptors and Toll-like receptor 2 (TLR2) and TLR4 (refs. 80,81). Fungal recognition induces intracellular signalling that culminates in eventual pathogen phagocytosis. Fungal opsonization with antibodies and C3b fragments of the complement enhances phagocytosis⁸². Following phagocytosis of the fungi, macrophages secrete cytokines including tumour necrosis factor (TNF), IL-1 β , IL-6, IL-12 and GM-CSF, which all promote the expression of chemokines, including CXCL1, CXCL2, and chemokine receptors (such as CXCR2)^{80,81}. These cytokines and chemokines attract additional innate immune cells, including neutrophils and monocytes, to the lung (Fig. 2).

Despite successful phagocytosis of the fungi, some virulence mechanisms of *C. neoformans* block intracellular pathogen killing responses in phagocytes⁸³. As a result, T cell help is required for effective clearance of phagocytosed fungi. After having phagocytosed the fungi, dendritic cells mature and express the costimulatory molecules CD80 and CD86 and the chemokine receptor CCR7, which directs dendritic cell migration towards CCL21-secreting local lymph nodes⁸⁴. Inside the lymph nodes, dendritic cells present *C. neoformans*-derived antigens to naive T and B lymphocytes⁸⁴ (Fig. 2). In addition, infected innate immune cells, including macrophages, secrete IL-12, which polarizes CD4⁺ T helper cells to a pro-inflammatory T helper 1 (T_H1) cell phenotype⁸⁵. CD4⁺ T_H1 cells in turn secrete IFN γ , which potentiates the killing capacity of phagocytic cells⁸⁵. The clearance of *C. neoformans* coincides with the development of an adaptive immune response that

enhances killing or containment of the fungi in granulomas⁷⁹ (Fig. 2). Therefore, successful containment of the fungus requires both innate and immune responses.

Host factors for disease reactivation

T cell-mediated immunity is crucial for controlling *C. neoformans* infection. Conditions associated with T cell defects predispose to disseminated cryptococcal disease (Fig. 2). These include HIV with low CD4⁺ T cell counts (usually <100 cells/μl); solid organ transplantation; use of immunosuppressive drugs, such as high-dose corticosteroids, azathioprine and cyclophosphamide; haematological and solid malignancies; idiopathic CD4⁺ lymphopenia; cytokine-specific autoantibodies; and genetic polymorphisms that impair immune cell function. Less commonly, chronic diseases such as diabetes mellitus, chronic lung disease, renal failure and liver disease impair T cell function, thereby conferring susceptibility to reactivation of latent cryptococcal infection^{86–88}. Pregnancy-related immunomodulation may increase the risk of disseminated cryptococcosis⁸⁹.

Autoantibody-associated syndromes targeting IFNγ or GM-CSF have been implicated in cryptococcal disease⁶⁶. The IL-12–IFNγ axis is required to ensure that phagocytic cells kill intracellular *C. neoformans*; thus, patients with defective IFNγ signalling, including those with IFNγ-specific autoantibodies, are unable to clear fungi⁹⁰. GM-CSF promotes the differentiation and functioning of alveolar macrophages including chemotaxis, phagolysosome maturation and microbicidal activity⁹¹. Patients with GM-CSF-specific autoantibodies are therefore at risk of acquiring cryptococcal meningitis, especially following infection with *C. gattii*^{65,66}.

Virulence factors and immune evasion

The polysaccharide capsule of cryptococci is the main virulence factor that protects the fungus from phagocytosis, intracellular killing and reactive oxygen species^{83,92,93} (Fig. 2). It is unsurprising that capsule size positively correlates with resistance to in vitro killing⁹³. Additionally, glucuronoxylomannan (GXM), the most abundant capsular polysaccharide, inhibits immune cell trafficking and facilitates fungal dissemination^{92,94}. Chitin, a component of the fungal cell wall, is another vital virulence factor that influences capsular structure, extracellular vesicle trafficking and protection from the surrounding environment⁹⁵. Fungi with reduced levels of chitosan (a chitin derivative) have ‘leaky melanin’ and are more sensitive to cell wall inhibitors and high temperatures^{96,97}. The term leaky melanin refers to decreased ability of the cryptococcal cell wall to retain melanin. Melanin functions as a scavenger for reactive nitrogen and oxygen species^{98,99}. Reactive nitrogen species and oxygen species are effector molecules released by human immune cells and contribute to microbial killing through induction of apoptosis. Melanin also makes the fungus cell wall thicker and more resistant to phagocytosis and intracellular killing.

Several cryptococcal enzymes contribute to immune evasion, including phenol oxidase and laccase, phospholipases and ureases (Fig. 2). Phenol oxidase and laccase enable *C. neoformans* to synthesize melanin, leading to melanin accumulation in the fungal cell wall – a process also known as melanization^{98,99}. Phospholipases involved in sphingolipid metabolism promote *C. neoformans* survival in the hostile intracellular environment of phagolysosomes that are characterized by oxidative, nitrosative and acidic stresses¹⁰⁰. Additionally, phospholipases confer resistance to antibody-mediated and complement-mediated phagocytosis in the CNS and promote brain damage¹⁰¹. The mechanism by which phospholipases protect against

phagocytosis is unclear but is possibly related to the formation of titan cells¹⁰². Phospholipase activity also promotes fungal adherence to the lung epithelia by disrupting surfactant and cell membranes of immune cells in the lungs^{103,104}. Finally, ureases, which promote nitrogen acquisition from the environment, help increase the pH in phagolysosomes^{105,106}. Urease activity complements melanization in virulence as ammonia released by urease promotes the melanization of distant fungal cells¹⁰⁷.

Dissemination to the CNS

Dissemination of the fungi from the lungs to the CNS occurs via the bloodstream and at this point, fungi are detectable in the blood by CrAg testing and fungal culture. *Cryptococcus* traverses the blood–brain barrier into the subarachnoid space via transcellular, paracellular or ‘trojan horse’ mechanisms (Fig. 2). During transcellular dissemination, the fungus adheres to and gets internalized by microvascular endothelial cells in the brain⁷⁶. Paracellular invasion is facilitated by *C. neoformans*-secreted metalloproteases, which enzymatically degrade intercellular junction adhesion molecules and the basement membrane to facilitate passage of the fungus into the subarachnoid space. In the trojan horse mechanism, phagocytic immune cells, mainly monocytes and macrophages, traffic phagocytosed *C. neoformans* into the CNS¹⁰⁸.

Immune responses in the brain

Invasion of the subarachnoid space leads to the recruitment of monocytes, macrophages, neutrophils, dendritic cells and microglia to the foci of infection (Fig. 2). Cytokines and chemokines are released after fungal invasion of the blood–brain barrier and alter the avidity and expression of endothelial cell adhesion molecules, such as L selectin, ICAM1, ICAM2, selectins and ICAM molecules, bind integrin on circulating immune cells and promote extravasation of immune cells into the CSF. Early during the disease course, neutrophilic pleocytosis may be found in the CSF. Neutrophils are critical in early clearance of *C. neoformans* from leptomeningeal capillaries¹⁰⁹.

The chemokine CCL2 attracts monocytes and macrophages to the subarachnoid space. In murine models, inflammatory monocytes have been shown to traffic phagocytosed *C. neoformans* to the subarachnoid space¹⁰⁸. M1 macrophages are protective against fungal infection and acquire their pro-inflammatory phenotype in the presence of IFNγ produced by T_H1 cells, natural killer cells and CD8⁺ T cells¹¹⁰. In the subarachnoid space of mice, however, inflammatory monocytes can be polarized towards an alternatively activated M2 phenotype which is permissive for fungal infections¹¹¹. In fact, patients with HIV–CM who survive the initial 2 weeks of treatment show increased levels of IFNγ in the CSF at baseline compared with those who die¹¹². Consistently, IFNγ adjunctive therapy has shown an increased rate of fungal clearance in two phase II randomized clinical trials in patients with HIV–CM^{113,114}.

Microglia, the main subset of CNS-resident macrophages, are self-replicating and are maintained by IL-34. In vitro studies have shown that microglia phagocytose *C. neoformans*, but the fungus survives and replicates in microglial phagosomes¹¹⁵. Microglia display increased phagocytosis in the presence of antibodies that specifically bind to GXM of the cryptococcal capsule, thereby inhibiting fungal growth¹¹⁶. Following phagocytosis, microglia present fungal antigens to T cells and secrete inflammatory cytokines including TNF, IL-1, IL-6 and IL-12 (ref. 117).

Activation of a T cell immune response is beneficial in controlling CNS cryptococcosis, but CD4⁺ T cell-mediated immune injury has been

described in murine models of fungal growth in the CNS¹¹⁸. The contribution of CD4⁺ T cell-mediated immune injury in human CNS disease outcomes remains a subject of inquiry.

B cells have been found to be unnecessary for protection against *C. neoformans* in mouse models of disease dissemination¹¹⁹. In mice, vaccine-acquired immunity against the fungus depends on CD4⁺ T cells rather than B cells¹¹⁹. Further, capsule-specific antibodies do not neutralize *C. neoformans* in the absence of T lymphocytes, and this phenomenon may explain recurrent cryptococcosis in people living with HIV who have not started treatment, have interrupted their treatment or are disengaged from care¹¹⁶. Nevertheless, B cells potentially have a role in regulating the immune response to *C. neoformans*, as implied by the positive association between expression of the immune checkpoint PDL1 on plasma cells and survival in patients with HIV–CM¹²⁰. Having a combination immune defect of T cell deficiency and B cell dysfunction may predispose to more severe disease or IRIS¹²¹.

Cryptococcal IRIS

Cryptococcal IRIS is a dysregulated inflammatory response to cryptococci that occurs when the immune system begins to recover following treatment with ART¹²². ‘Unmasking’ IRIS is characterized by overt clinical symptoms of a previously undiagnosed subclinical infection soon after ART is started. Unmasking IRIS events commonly may present with more acute presentations or atypical manifestations in unusual anatomical locations. ‘Paradoxical’ IRIS refers to the worsening of a previously diagnosed and treated infection after ART is started^{122,123}.

Risk factors driving the onset of paradoxical cryptococcal IRIS can generally be grouped as pathogenic factors (initial fungal burden); host immune response factors (paucity of baseline immune response¹²⁴; GXM-specific antibody responses in the CSF¹²¹; immune system dysfunction with poor macrophage killing^{125,126}; impaired clearance of cryptococcal yeast cells¹²⁷; and dysregulated homeostatic regulatory mechanisms resulting in exaggerated inflammatory responses^{41,128}); and the timing of ART initiation³⁴ (Box 1).

Diagnosis, screening and prevention

Diagnosis of primary infection

CrAg testing on CSF, serum, plasma or whole blood, performed using a lateral flow assay (LFA), a latex agglutination assay or an enzyme-linked immunosorbent assay is the cornerstone in prompt cryptococcal diagnosis. All available diagnostic tests are outlined in Table 1. Studies have shown that CrAg LFA by IMMY (Norman, OK) is currently the best performing commercially available assay that can be used as a point-of-care test. Its performance is superior to that of other diagnostics, with sensitivity and specificity beyond 99%, when applied to CSF samples^{129–132}. Other CrAg LFAs have been developed, but their diagnostic performance is suboptimal^{133–135}.

In HIV-negative samples or very early after cryptococcal infection, the CrAg titre in CSF can be very low or at times absent, and patients may slowly develop a chronic presentation that can be mistaken for another pathology such as tuberculous meningitis or coccidioidomycosis^{52,67}. Repeat CSF testing may be necessary, and we recommend always testing for CrAg also in the blood in the setting of unexplained meningitis^{52,136}. Cerebral CT and MRI are useful in detecting complications such as cerebral cryptococcoma, which is a space-occupying mass loaded with *Cryptococcus* yeasts. Cryptococcoma is most frequently found in immunocompetent hosts^{137,138}. Surgical resection, histopathology and culture may be used in patients with large CNS lesions where confirmation is needed¹³⁹.

Diagnosis of relapse

CrAg testing cannot distinguish among cryptococcal meningitis relapse, paradoxical IRIS and a new non-cryptococcal CNS diagnosis, as CSF remains positive for CrAg for months to years after initial diagnosis¹⁴⁰. CSF cryptococcal culture is the only definitive diagnostic test to validate relapsed infection, yet results are obtained only 5–14 days later, which is too late to facilitate timely clinical decision making. Without access to timely confirmatory results, clinicians are forced to make empirical treatment decisions about the application of toxic antifungal therapy for suspected relapse versus steroid therapy for suspected paradoxical IRIS, often with detrimental consequences if incorrect¹⁴¹. In a study analysing adults with recurrence of HIV–CM symptoms, a multiplex PCR assay correctly classified 10 of 11 individuals in terms of relapse versus paradoxical IRIS, but the current FDA-approved PCR multiplex assay has poor sensitivity when CSF quantitative culture yields <100 colony-forming units per millilitre and high costs¹⁴². A real-time quantitative PCR assay for *Cryptococcus* is under development, and offers promise that more sensitive tools to differentiate between relapse and IRIS will soon become available¹⁴³.

Box 1

Risk factors for cryptococcal immune reconstitution inflammatory syndrome following ART

Microbiological

- Higher fungal burden or antigen titre at diagnosis^{30,31,41,113}.
- Positive residual culture at the end of induction therapy when starting fluconazole 400mg for consolidation therapy^{113,127}. Excess risk was not observed when using fluconazole 800mg for consolidation therapy²³³.

Immunological

- Lower pre-antiretroviral therapy (ART) CD4⁺ T cell count^{113,234}.
- A robust immunological response to ART with more than fourfold CD4⁺ T cell increase^{37,235}.
- Elevated values of C-reactive protein in the blood^{36,37,41}.
- Low levels of IgM, laminarin-binding IgM, glucuronoxylomannan-specific IgM in the plasma at diagnosis¹²¹.
- Paucity of cerebrospinal fluid (CSF) inflammation, denoted by white cells (<25 cells/μl) and total protein (<50 mg/dl) in the CSF¹²⁴.
- Trafficking of inflammatory monocytes, activated CD4⁺ T cells, natural killer cells into the CNS compartment²³⁶.
- Low levels of interferon-γ, tumour necrosis factor, IL-2, IL-6, IL-8 and IL-17 in the CSF^{113,124,127}.

Therapeutic

ART initiation within 4 weeks of therapy for HIV-associated cryptococcal meningitis^{34,37,179–181}.

Table 1 | Diagnostic tests for cryptococcal meningitis^{129,132}

Assay	Sensitivity (%)	Specificity (%)	Pros	Cons
CSF fungal culture ^a	82.4–94.2	100	Can be used for diagnosis of cryptococcal meningitis relapse	Sensitivity dependent on volume of CSF sample
CrAg lateral flow assay	99.3	99.1	Rapid results (within 10 min); low cost; storage at room temperature; ease of use	Inability to differentiate cryptococcal meningitis relapse from paradoxical IRIS
CrAg latex agglutination ^a	97.0–97.8	85.9–100	Turnaround time shorter than fungal culture	Requires refrigeration of reagents, laboratory infrastructure and expertise
Indian ink microscopy ^a	86.1	97.3	Rapid results; low cost; storage at room temperature; ease of use	Sensitivity highly dependent on fungal burden; false positives from non-viable yeasts
Multiplex PCR ^b	82	98	Turnaround time shorter than for fungal culture	Sensitivity dependent on fungal burden; low sensitivity at <100 CFU/ml CSF

CFU, colony-forming units; CrAg, cryptococcal antigen; CSF, cerebrospinal fluid; IRIS, immune reconstitution inflammatory syndrome. ^aReference test: a composite gold standard defined as CSF culture-positive or a culture-negative sample with two or more positive test results (Indian ink microscopy, CrAg latex or CrAg lateral flow assay) and without an alternative aetiological explanation¹²⁹. ^bBioFire FilmArray meningitis/encephalitis panel. Reference standard test for Multiplex PCR: CrAg lateral flow assay in patients presenting with the first episode of cryptococcal meningitis, and fungal culture in patients with a previous history of cryptococcosis¹³².

Prevention and screening in people with HIV

There are currently no vaccines available for preventing cryptococcosis, but preclinical studies using recombinant vaccines of a chitin deacetylase subunit (Cda2) administered with an adjuvant show potential¹⁴⁴. However, the commercial viability of recombinant vaccines for HIV–CM is expected to involve significant challenges. Screening for CrAg in blood is recommended in people living with AHD¹⁴⁵. In 2011, WHO Rapid Advice introduced CrAg screening and pre-emptive fluconazole treatment based on observational evidence, including evidence from a Ugandan prospective cohort demonstrating that patients with HIV and cryptococcal antigenaemia who received low-dose fluconazole (400 mg per day or less) had a survival benefit^{146,147}. In addition, a ‘screen-and-treat’ approach was modelled as being more cost-saving and life-saving in comparison with the ‘no screening’ or ‘universal prophylaxis’ approaches¹⁴. A multisite randomized prospective trial (REMSTART) confirmed previous observational findings, showing that CrAg screening and pre-emptive treatment of patients with cryptococcal antigenaemia contributes to a mortality risk reduction of around one-third⁴⁷.

Prospective screening studies have identified a clinical entity described as subclinical cryptococcal meningitis, that affects approximately one-third of individuals with cryptococcal antigenaemia and is associated with high CrAg titres in the blood, *Cryptococcus* in the CSF, but no overt clinical features of meningitis, such as severe headache, confusion, seizures or reduced consciousness^{49,148,149}. WHO guidelines, therefore, recommend lumbar puncture to exclude subclinical cryptococcal meningitis in all CrAg-positive patients irrespective of symptoms. However, some experts recommend that decisions about the need for lumbar puncture be guided by plasma CrAg titres and symptoms, recognizing that the risk of asymptomatic CNS disease is low among individuals with a plasma CrAg LFA titre of ≤1:80, and becomes very common in those with a CrAg LFA titre of ≥1:1,280 (ref. 149) (Fig. 3a).

Screening for co-infections

Co-prevalent opportunistic infections are likely to contribute to poor outcomes of HIV–CM^{150–152}. Interventions to optimize prevention, and/or early diagnosis and treatment of opportunistic infections are therefore critical.

Approximately 25% of hospitalized patients with HIV–CM also have active tuberculosis (TB), with TB co-infection being associated

with an increase of >50% in the risk of mortality¹⁵⁰. The considerable overlap in non-specific symptoms between TB and cryptococcosis means that without systematic screening, a TB diagnosis will be missed. Accordingly, the WHO recommends universal urine testing for TB LAM (detecting the TB antigen lipoarabinomannan) for all hospitalized patients with AHD, including those with cryptococcal meningitis¹⁵³. Low complexity automated PCR with reverse transcription applied to sputum samples is the first-line diagnostic for pulmonary TB and should be utilized whenever a sputum sample can be obtained¹⁵⁴, but given the predominance of extrapulmonary TB in AHD, and the frequent inability to produce sputum due to severe disease states associated with cryptococcal meningitis, non-sputum-based TB diagnostics are required in this high-risk population¹⁵³.

Owing to profound immunocompromise, in-dwelling medical devices and prolonged hospitalization, an estimated 5–15% of patients with HIV–CM acquire a concurrent bloodstream infection during hospitalization, with a high proportion of multidrug resistant infections¹⁵⁵. Blood cultures remain the gold standard for diagnosis, but diagnosis with novel multiplex PCR carries the potential to increase yield and decrease time to result¹⁵⁶. Other than cotrimoxazole, broader antimicrobial prophylaxis including azithromycin is not currently recommended due to concerns relating to antimicrobial resistance¹⁵⁷. Meningococcal and pneumococcal vaccination should be offered to all individuals with AHD¹⁵³.

Cytomegalovirus (CMV) reactivation is common in AHD. Among adults with HIV–CM, the prevalence of CMV viraemia is reported to be between 36% and 52%, and is associated with a threefold increased risk of mortality compared with those without CMV viraemia^{151,152}. CMV quantitative PCR is the most sensitive method for detecting CMV. When utilized in non-HIV immunocompromising conditions other than HIV infection, such as stem cell transplants, to guide CMV prophylaxis or treatment, high CMV viraemia in the blood is a good predictor of CMV disease¹⁵⁸. It is probable that quantitative PCR CMV screening would also facilitate risk stratification in patients with AHD, but viral load cut-offs need to be defined. Guidelines currently highlight the importance of early ART initiation rather than anti-CMV prophylaxis due to concerns regarding the side effects, drug resistance and cost-effectiveness of CMV-targeting drugs, as well as the lack of a proven survival benefit associated with older anti-CMV drugs, such as oral ganciclovir^{159,160}. In cryptococcal meningitis, however, the early ART strategy is untenable due to the risk of IRIS. Investigation

of whether anti-CMV prophylaxis or treatment (for example, using valganciclovir or letermovir) prior to ART may improve outcomes in this high-risk population is warranted¹⁶¹.

Additional important co-pathogens that may contribute to poor outcomes in cryptococcal meningitis include cerebral toxoplasmosis, *Pneumocystis jirovecii* pneumonia, and disseminated histoplasmosis; however, the global burden of morbidity and mortality attributable to these infections is poorly characterized because appropriate diagnostic facilities are lacking in most settings with a high AHD burden¹⁵³.

Management

Management of HIV–CM

Treatment of cryptococcal meningitis is divided into three phases: induction, consolidation, and maintenance or secondary prophylaxis¹⁶². While guidelines about the consolidation and maintenance phases have remained largely unchanged and are managed with fluconazole, the induction phase has gone through several iterations to maximize survival. Historically, the induction phase consisted of a 14-day course of an amphotericin B deoxycholate-based regimen¹³⁹. Amphotericin B deoxycholate is notoriously toxic, and prolonged 14-day courses are associated with severe side effects such as anaemia, hypokalaemia, hypomagnesaemia and nephrotoxicity^{163–165}. Owing to the poor tolerance of extended amphotericin B therapy and high cryptococcal mortality in routine care settings, shorter courses have been tested^{8,166,167}.

Two landmark randomized clinical trials conducted in Africa in patients living with HIV demonstrated that it is possible to achieve a 10-week mortality rate below 30% with shorter courses of amphotericin B. Based on the Advancing Cryptococcal Treatments for Africa (ACTA) and the Ambisome Therapy Induction Optimization (AMBITION-cm) trials, abbreviated courses (≤ 7 days) of amphotericin-based induction therapy are now preferred for the management of HIV–CM^{12,13} (Box 2).

The ACTA trial sought to determine whether 7-day courses of amphotericin B deoxycholate-based regimens are non-inferior to 14-day courses¹². This trial additionally tested an amphotericin-sparing combination of flucytosine 100 mg/kg/day and fluconazole 1,200 mg/day for 14 days. The 7-day amphotericin-based regimens were found to be non-inferior to the 14-day regimens. Significantly, 7 days of amphotericin 1 mg/kg/day plus flucytosine 100 mg/kg/day was associated with the lowest 10-week mortality (24.2%) when compared with all other regimens, including 2 weeks of amphotericin plus flucytosine¹². Additionally, the ACTA trial demonstrated that flucytosine is a superior antifungal partner to fluconazole¹². Despite having the slowest rate of *Cryptococcus* clearance from the CSF, the amphotericin-sparing arm was the second best-performing arm with 10-week mortality of 35%, and this regimen was also the safest¹². As a result, the 1 week of amphotericin B and flucytosine, and 2 weeks of fluconazole and flucytosine ACTA trial regimens became the WHO recommended first-line and second-line regimens in 2018 for the management of HIV–CM¹⁶⁸.

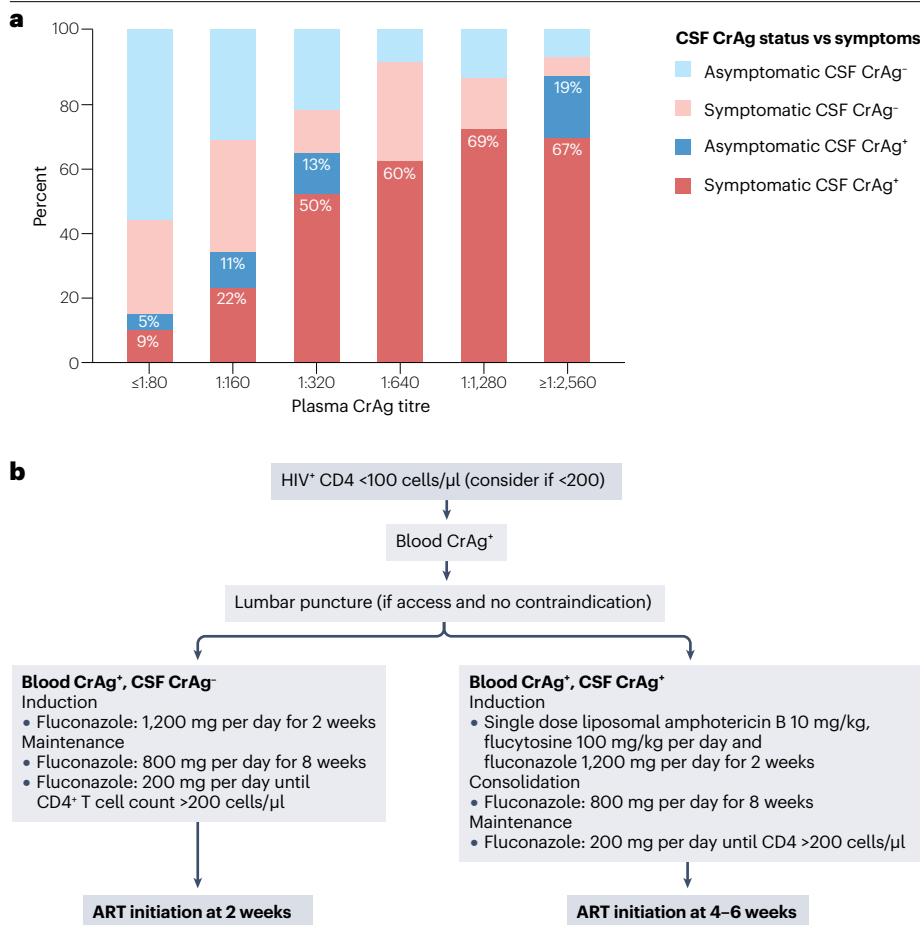


Fig. 3 | Cryptococcal antigen screening in HIV–CM.

a, Association between cryptococcal antigen (CrAg) titres in the plasma of individuals living with HIV reporting meningitis symptoms (headache; that is, symptomatic) and CrAg detection in the cerebrospinal fluid (CSF)¹⁴⁹. Data are based on multiple cohorts from Ethiopia, South Africa, Tanzania and Uganda where lumbar puncture among individuals with CrAg-positive plasma tests, irrespective of the presence of meningitis symptoms, was instituted, as recommended by 2018 and 2022 World Health Organization guidelines^{148,176,231,232}. Mortality is significantly lower in asymptomatic persons and increases with CrAg titre. Survival by titre is summarized elsewhere¹⁴⁹. **b**, HIV-associated cryptococcal meningitis (HIV–CM) management following CrAg screening and pre-emptive treatment. Recommended timing of antiretroviral therapy (ART) initiation (2 weeks) in CrAg-positive individuals is based on expert opinion.

Box 2

The 2022 WHO treatment guidelines for HIV–CM^{145,168}

Induction phase

A single high dose (10 mg/kg) of liposomal amphotericin B with 14 days of flucytosine (100 mg/kg per day divided into four doses per day) and fluconazole (1,200 mg per day in adults; 12 mg/kg per day in children and adolescents up to a maximum of 800 mg per day).

Alternative therapy in the induction phase

- If liposomal amphotericin B is not available: a 7-day course of amphotericin B deoxycholate (1 mg/kg per day) and flucytosine (100 mg/kg per day, divided into four doses per day) followed by 7 days of fluconazole (1,200 mg per day in adults and 12 mg/kg per day in children and adolescents up to a maximum of 800 mg per day).
- If no amphotericin B deoxycholate is available: 14 days of fluconazole (1,200 mg per day, 12 mg/kg per day in children and adolescents) and flucytosine (100 mg/kg per day, divided into four doses per day).
- If flucytosine is not available: 14 days of liposomal amphotericin B (3–4 mg/kg per day) and fluconazole (1,200 mg per day, 12 mg/kg per day for children and adolescents up to a maximum of 800 mg per day).
- If liposomal amphotericin B and flucytosine are not available: 14 days of amphotericin B deoxycholate (1 mg/kg per day) and fluconazole (1,200 mg per day, 12 mg/kg per day in children and adolescents up to a maximum of 800 mg per day).

Consolidation phase

- Fluconazole (800 mg per day in adults or 6–12 mg/kg per day in children and adolescents up to a maximum of 800 mg per day) is recommended for the consolidation phase (for 8 weeks following the induction phase to 10 weeks).
- Start antiretroviral therapy (ART) between week 4 and week 6 from initiation of antifungal treatment.

Maintenance phase

Fluconazole (200 mg per day in adults or 6 mg/kg per day in children and adolescents) until immune reconstitution (CD4⁺ T cell counts >200/μl) and suppression of viral loads on ART.

HIV–CM, HIV-associated cryptococcal meningitis; WHO, World Health Organization.

The liposomal form of amphotericin is associated with reduced drug-related toxicities compared to amphotericin B deoxycholate and has a long half-life in the CNS¹⁶⁹. A single, high dose of 10 mg/kg of liposomal amphotericin B was demonstrated to be non-inferior to daily dosing of liposomal amphotericin B when combined with fluconazole in the phase II AMBITION-cm trial¹³. Given the emerging evidence from the ACTA trial on the importance of flucytosine, this led to the AMBITION-cm phase III non-inferiority trial comparing a single

10-mg/kg dose of liposomal amphotericin combined with 14 days of flucytosine (100 mg/kg) and fluconazole (1,200 mg) with standard of care. The standard of care was 7 days of amphotericin (1 mg/kg/day) and flucytosine (100 mg/kg) followed by 7 days of fluconazole (1,200 mg). This trial demonstrated that treatment with single-dose liposomal amphotericin was non-inferior to the control standard of care in terms of survival, with equivalent CSF fungal clearance over 14 days¹³. The AMBITION-cm regimen was also associated with fewer grade 3 and 4 adverse events, including anaemia, nephrotoxicity and hypokalaemia, with no additional risk of cytopenias or transaminitis¹³. Moreover, the AMBITION-cm regimen was cost-effective in resource-limited settings and highly acceptable to participants and health-care providers^{170,171}. The AMBITION-cm regimen was subsequently adopted as the WHO recommended in 2022 regimen for the management of HIV–CM¹⁴⁵.

Current guidelines for HIV–CM in high-income countries recommend 2 weeks of liposomal amphotericin B and flucytosine for induction therapy; however, this regimen represents an evolution of treatment over time and has never been tested in a randomized controlled trial and there has been no direct comparison with the AMBITION-cm regimen¹⁶². Harrison et al. argued that the AMBITION-cm regimen should be adopted across all settings due to its high rates of CSF sterility at 2 weeks and the absence of relapse cases occurring in the trial, and because the single-dose regimen reduces the occurrence of drug toxicities associated with prolonged courses of amphotericin¹⁷².

The use of corticosteroids is not recommended as a component of induction treatment of HIV–CM as it was associated with increased mortality in the CryptoDex trial, a large randomized controlled trial in patients with HIV–CM. Steroids may still be considered in particular patients who do not respond to treatment with antifungals despite a sterile CSF culture and/or upon identification of inflammatory brain lesions¹⁷³, including in some patients with paradoxical IRIS. Dexamethasone should not be used as a substitute for lumbar puncture or a CNS shunt for the management of raised intracranial pressure (ICP)^{173,174}.

Pre-emptive therapy for cryptococcal antigenaemia. The WHO recommends high-dose fluconazole with 800–1,200 mg per day for 2 weeks in all individuals living with HIV who develop cryptococcal antigenaemia without any other symptoms of cryptococcal meningitis, irrespective of titre, followed by consolidation (800 mg per day for 8 weeks) and maintenance therapy (200 mg per day) for at least a year to allow for immune reconstitution on ART¹⁴⁵ (Fig. 3b). Guidelines in southern African countries recommend an increased induction fluconazole dose of 1,200 mg based on a general evolution over time to higher doses of fluconazole, which have been well tolerated, including for the treatment of meningitis¹⁷⁵.

Fluconazole monotherapy may not be adequate for preventing disease progression in CrAg-positive patients, particularly those who have undiagnosed subclinical cryptococcal meningitis¹⁷⁶. A study investigating the cause of death in 17 asymptomatic CrAg-positive patients who died within 6 months of initiation of treatment with 800 mg fluconazole, attributed 71% of the deaths to cryptococcal disease as an immediate or contributing cause⁴⁸. In response to a growing recognition that fluconazole monotherapy may be suboptimal treatment for cryptococcal antigenaemia, two randomized controlled trials aim to investigate combination treatments: the ACACIA Trial (Uganda) will test liposomal amphotericin B 10 mg/kg plus fluconazole (NCT03945448)¹⁷⁷; and the EFFECT Trial (South Africa and Tanzania) will test flucytosine plus fluconazole treatment (ISRCTN30579828)¹⁷⁸ for reducing all-cause mortality in patients with HIV and cryptococcal

antigenaemia. These trials will also assess if combination drug regimens should be targeted to individuals at higher risk of disease progression, as stratified based on CrAg titre.

Timing of ART. Despite widespread availability of ART worldwide, the incidence of cryptococcal meningitis remains high⁷. Before 2014, it was considered imperative to initiate ART as soon as possible, without any concerns about the timing of ART initiation in the context of an existing opportunistic infection. Five trials have examined the impact of the timing of ART initiation on outcomes in the setting of cryptococcal meningitis. The ACTG 5164 trial showed that ART initiation within 14 days of diagnosis of HIV–CM reduced death and AIDS progression as compared with ART initiated 4 weeks later, albeit with non-significant results. However, the trial included only 41 participants with cryptococcosis and was under-powered to influence guidelines¹⁷⁹. Conflicting results were found in a trial that was conducted in Zimbabwe and involved 54 patients with HIV and cryptococcosis who were treated with fluconazole monotherapy: participants randomly assigned to ART initiation within 24 h of meningitis diagnosis had a higher risk of death than those in whom ART was deferred (median 10 weeks later)¹⁸⁰. Another randomized trial in Botswana involving 27 patients with cryptococcosis showed a higher risk of IRIS among participants who were randomized to early ART, without a survival benefit from deferred ART¹⁸¹. The conflicting, under-powered results of the above-mentioned trials created an equipoise, indicating that the timing of ART initiation in the setting of HIV–CM should accommodate a balanced consideration of the untoward risk of an occasionally fatal ART complication, IRIS and the benefit of ART^{179–181}.

The COAT trial, which involved 177 patients with HIV–CM definitively concluded that deferring ART for 4–6 weeks after the diagnosis of meningitis conferred an absolute survival benefit of 15% as compared with initiating ART within 1–2 weeks³⁴. These results were replicated in a randomized trial with 102 participants with HIV–CM from China which demonstrated higher mortality with ART initiation at <4 weeks versus >4 weeks after meningitis diagnosis³⁵.

Based on the above findings, clinicians can now make informed decisions about ART initiation following HIV–CM diagnosis. However, it remains unclear whether ART should be interrupted when HIV–CM is diagnosed up to 14 days after ART initiation. In a cohort of 605 patients who received amphotericin-based therapy following a first-episode of HIV–CM, those in whom ART was initiated up to 14 days before the diagnosis of cryptococcal meningitis had a significantly higher 2-week mortality rate (47%) compared with patients who had been on ART for 15–182 days prior to diagnosis of cryptococcal meningitis and had a 2-week mortality rate of 14%²⁶. Although these findings have not yet been replicated in other cohorts, a group of experts have suggested that ART interruption may lower mortality risk in patients diagnosed with HIV–CM within 14 days of ART initiation¹⁸². However, further investigation is warranted.

Some controversy has arisen in 2023 whereby some believe that the randomized clinical trial data on ART timing after cryptococcal meningitis is not applicable to high-income settings, based on observational pooled cohort data from 630 people collected from 1996 to 2012 (ref. 183). There are substantial limitations of these observational data, not least that 70% had missing outcome data or were unjustifiably excluded from analysis¹⁸³. Delaying ART initiation by >4 weeks after cryptococcal meningitis remains the recommended strategy.

Cryptococcal IRIS. The occurrence of or severe cryptococcal IRIS should be prevented by early diagnosis of HIV infection, with ART

initiation, CrAg screening and pre-emptive therapy, using appropriate antifungal therapy. ART delay according to current guidelines should decrease the risk of IRIS.

When cryptococcal IRIS occurs, it is important that symptomatic management is considered. Management consists of controlling raised ICP via therapeutic lumbar puncture¹⁷⁵, excluding co-infections, and therapeutic interventions to decrease inflammation, including corticosteroids¹⁸⁴. Thalidomide and TNF-specific monoclonal antibodies have been used in patients with corticosteroid-refractory IRIS^{185,186}.

Management of non-HIV–CM

As non-HIV–CM is increasingly being diagnosed, particularly in high-income countries, the paucity of evidence from randomized controlled trials about the management of non-HIV–CM, particularly a lack of current data using what have become standard doses of antifungals, becomes increasingly apparent¹⁸⁷. Guidelines of the Infectious Diseases Society of America (IDSA), that were published in 2010, recommend standard 2-week amphotericin and flucytosine induction therapy for organ transplant recipients with non-HIV–CM. In non-HIV and non-transplant patients with cryptococcal meningitis, the recommendation is amphotericin and flucytosine induction therapy for at least 4 weeks with guidance to extend to 6 weeks in the presence of neurological complications and/or positive CSF culture at week 2 after therapy initiation, although the guidelines authors do acknowledge the paucity of evidence and lack of consensus on this topic¹³⁹. There are no data on high-dose liposomal amphotericin B regimens for non-HIV–CM, and the findings of the AMBITION-cm trial may not be transferrable to patients with non-HIV–CM due to the differences between pathologies, particularly in terms of host immune function and the absence of any treatment comparable to ART that can rapidly restore the immune system.

Cryptococcal post-infectious inflammatory response syndrome (PIIRS) is an excessive inflammatory reaction that may occur in patients with non-HIV–CM and no apparent immunocompromising condition, resulting in host damage. PIIRS is diagnosed based on several factors, including but not limited to clinical deterioration, new lesions appearing on brain imaging, raised ICP in the presence of a sterile CSF culture, elevated CSF white cell count, and low CSF glucose levels¹⁸⁷. In a single-arm observational study in 15 patients with non-HIV–CM and PIIRS, tapered courses of steroids dosed as 1 week of high-dose methylprednisolone (1 g/day) followed by oral prednisone 1 mg/kg/day were associated with improvements in PIIRS-related complications of cryptococcal meningitis, including vision and hearing impairment¹⁸⁸. IDSA guidelines suggest steroid courses of 2–6 weeks at tapering doses starting at 0.5–1.0 mg/kg/day prednisolone equivalent for PIIRS.

Ancillary support

Amphotericin B deoxycholate causes life-threatening side effects, including electrolyte abnormalities (hypokalaemia and hypomagnesaemia), anaemia, kidney injury, thrombophlebitis and consequent bacteraemia^{155,163,164,189}. Although protocols for standardized electrolyte supplementation and pre-emptive hydration have been effective in reducing mortality, their consistent implementation is challenging, especially in resource-constrained settings^{163,164}. Single high-dose liposomal amphotericin, which is less toxic, is therefore a much more desirable treatment option in such settings¹³.

However, ancillary support for patients with cryptococcal meningitis has an important survival benefit and is multi-modality. Severe baseline hyponatraemia (with serum sodium levels of <125 mmol/l)

occurs in up to 15% of patients with cryptococcal meningitis, and this complication is associated with a doubling in 2-week mortality and 30-day mortality risks¹⁹⁰. The development of hyponatraemia in patients with cryptococcal meningitis is likely to be a multifactorial insult, in which raised ICP, high quantitative cryptococcal cultures and seizures, leading to either the syndrome of inappropriate antidiuretic hormone secretion (SIADH) or cerebral salt wasting (CSW). However, laboratory tests to precisely differentiate between SIADH and CSW and guide management are often inaccessible in low-resource settings. Further research is needed to develop a standardized approach to hyponatraemia that does not improve with management of cryptococcal meningitis.

An objective assessment of impaired consciousness resulting in a Glasgow Coma Scale (GCS) score lower than 15 at diagnosis is a strong independent predictor of acute mortality; therefore, management of altered mental status is likely to further improve survival. A baseline GCS of <15 is associated with a fivefold increase in the probability of death³⁹ and is linked to increased ICP, seizures, hyponatraemia and elevated CSF lactate (>5 mmol/l)^{190–193}. Seizures are common in patients with cryptococcal meningitis, occurring in 28% of patients, and are associated with a higher 10-week mortality risk¹⁹². Thus, ancillary support for patients with cryptococcal meningitis should include neurological supportive care that incorporates aggressive management of ICP, treatment of hyponatraemia and seizures. The selection and duration of antiepileptic drugs to control seizures is influenced by the individual's medical history, comorbidities and potential drug–drug interactions.

Increased ICP (CSF opening pressure >20 cmH₂O) is common in patients with CM and is associated with significant mortality and morbidity. Guidelines recommend aggressive management of raised ICP through serial lumbar punctures, lumbar drain placement or ventriculoperitoneal shunting until ICP has normalized and symptoms have resolved (Table 2). While measurement of baseline opening pressure is

encouraged to determine the need for subsequent therapeutic lumbar punctures, it has previously been shown that one therapeutic lumbar puncture in the first week, irrespective of baseline opening pressure, is associated with a 69% relative improvement in survival in the first 10 days¹⁹⁴. Kagimu et al. also showed that a baseline opening pressure >35 cmH₂O is associated with a higher mortality, while Bicanic et al. did not find an association between baseline opening pressure and 2-week and 10-week outcomes when applying a protocolized schedule of therapeutic lumbar punctures^{13,195,196}. Therefore, we recommend that at a minimum, scheduled lumbar puncture be performed on day 3 after diagnosis and prior to discharge in all persons with cryptococcal meningitis, irrespective of baseline opening pressure (Table 2).

Quality of life

Mortality remains high in the first 6 months after diagnosis of cryptococcal meningitis, and there is a high prevalence of concurrent disability and neurocognitive impairment within the first 6 to 12 months after diagnosis^{40,197}. Quality of life assessment among individuals having completed treatment for cryptococcal meningitis revealed that those with a self-perceived low quality of life at week 10 after diagnosis had a higher mortality rate within the first 6 months compared with those with higher self-perceived quality of life at week 10 after diagnosis^{198,199}. Data on long-term (1 year and beyond) quality of life are needed. Cranial nerve impairments resulting in vision loss and hearing loss possibly contribute to long-term disability and low quality of life in individuals who have survived after a CM diagnosis^{200–202}. Vision loss in individuals with cryptococcal meningitis can occur as a presenting symptom or a complication. Rapid onset (<3 days) is attributed to optic nerve infiltration or inflammatory arachnoiditis and may occur without papilloedema or increased ICP²⁰³. Gradual onset (>3 days) is linked to uncontrolled raised ICP²⁰³. Temporary vision loss is often preceded by diplopia or decreased vision and improves with antifungal treatment and management of raised ICP, whereas irreversible loss is commonly

Table 2 | Guidelines and consensus recommendation for the management of raised intracranial pressure in HIV-associated and non-HIV-associated cryptococcal meningitis

	IDSA	Southern Africa	WHO	Consensus*
Baseline LP	Measure baseline OP If OP >25 cmH ₂ O, remove CSF until OP <20 cmH ₂ O or reduced by 50%	Measure baseline OP If OP >25 cmH ₂ O, remove 10–30 ml of CSF until OP <20 cmH ₂ O or reduced by 50%	Measure baseline OP If OP >25 cmH ₂ O, remove 20–30 ml of CSF until OP <20 cmH ₂ O or reduced by 50%	Measure baseline OP If OP >25 cmH ₂ O, remove CSF until OP has normalized to <20 cmH ₂ O If unable to measure OP, recommend large-volume CSF removal (20–25 ml)
Therapeutic LP	If persistently raised ICP >25 cmH ₂ O and/or symptoms of raised ICP, repeat LP daily until CSF pressure and symptoms remain resolved for 2 days Consider lumbar drain, ventriculostomy or VP shunt if continued raised ICP	Repeat LP whenever there are signs or symptoms of raised ICP If persistently raised ICP and failure to respond to daily LPs for more than 1 week, consider lumbar drain or shunting procedures	If baseline OP >25 cmH ₂ O and/or symptoms of raised ICP, repeat LP daily until OP has normalized and symptoms resolved for 2 days Remove ~20–30 ml CSF with each LP Early repeat of LP (day 3) with measurement of OP to assess for raised ICP in the absence of symptoms of raised ICP Consider lumbar drain or VP shunt if continued raised ICP	If baseline OP >25 cmH ₂ O and/or symptoms of raised ICP, perform large-volume CSF removal daily until OP has normalized and symptoms resolved If unable to measure baseline OP, repeat a minimum two subsequent LPs, on day 3 and ideally day 7, or prior to discharge Consider lumbar drain or VP shunt if continued raised ICP
Adjunctive therapies	Mannitol, acetazolamide and corticosteroids should not be used to control raised ICP	NA	Mannitol, acetazolamide, furosemide or corticosteroids should not be used to control raised ICP	Mannitol, acetazolamide and corticosteroids should not be used to control raised ICP

CSF, cerebrospinal fluid; ICP, intracranial pressure; IDSA, Infectious Diseases Society of America; LP, lumbar puncture; NA, not available; OP, opening pressure; VP, ventriculoperitoneal shunt; WHO, World Health Organization. *Consensus recommendations are based on the expert opinion of panel attendees at the 11th International Conference on Cryptococcus and Cryptococcosis session on Therapeutic Lumbar Punctures in Cryptococcal Meningitis in Kampala, Uganda, January 2023.

associated with optic nerve damage from increased ICP²⁰³. The incidence rate of sensorineural hearing loss among patients with CM is still unknown, and hearing loss might be associated with temporal bone invasion by *Cryptococcus*, damage to spiral ganglion cells and cochlear nerve fibres, or cryptococcal meningeal infiltration^{204,205}. Sensorineural hearing loss is more common in individuals with increased ICP and accompanying visual impairment²⁰⁴. The course of hearing loss varies, ranging from progression to permanent hearing loss, stabilization with residual hearing loss, or complete restoration with antifungal therapy and ICP decompression²⁰⁴.

Individuals with cryptococcal meningitis may initially present with psychiatric symptoms such as mania, depression and early signs of neurocognitive impairment at the time of diagnosis²⁰⁶. Depression rates among survivors with HIV are high (67% at 1 month, 44% at 3 months after diagnosis) and are associated with baseline altered mental status and increased distance from a health-care centre, indicating that delays in care and severe infection result in higher rates of depression²⁰⁷. Long-term data on neurological sequelae in cryptococcal meningitis are limited, and the existing literature exhibits methodological and analytical heterogeneity⁴⁰. Reports of disability among survivors of cryptococcal meningitis at 1 year after diagnosis vary from 11% to 69.2%⁴⁰. A longitudinal assessment of neurocognitive performance utilizing a battery of neuropsychological tests that evaluate eight cognitive domains demonstrated impaired neurocognitive performance in 89% of individuals at 1 month, in 59% at 3 months and in 41% at 6 months after diagnosis²⁰⁸. Overall, neurocognitive performance continues to improve during the first year, with residual impairment noted in cognitive domains of motor speed, and gross motor and executive function²⁰⁸. Whether the new induction regimens will impact long-term outcomes, including impaired neurocognitive performance, is a subject of further study. In the interim, strengthening rehabilitation services, including physical, occupational and cognitive rehabilitation is needed.

Outlook

The armamentarium to decrease the morbidity and mortality associated with cryptococcal meningitis has expanded over the past two decades. This arsenal includes CrAg LFA for prompt diagnosis, serum CrAg screening and pre-emptive antifungal therapy among persons with HIV and cryptococcal antigenaemia^{209–211}, therapeutic lumbar puncture^{194,196}, delaying ART initiation until after the diagnosis of cryptococcal meningitis in ART-naïve persons living with HIV³⁴, and the current development of shorter and more efficient and cost-effective¹⁷⁰ fungicidal regimens alongside adjunctive pre-supplementation with electrolytes¹⁶⁴.

Increasingly more individuals with HIV–CM are ART-experienced globally, suggesting that ART alone is not sufficient to eliminate the incidence of HIV–CM^{12,13,23,26,34}. Lack of knowledge about cryptococcal meningitis among the general population results in lumbar puncture refusal, and a low index of suspicion among health-care providers leads to delays in cryptococcal diagnosis, with a negative impact on outcomes²¹². A study in rural Uganda showed that 70% of patients who died following a HIV–CM diagnosis had sought care three or more times before the diagnosis was made. Additionally, only 10% of patients and 40% of family members knew about cryptococcal meningitis as a comorbidity of HIV infection²¹³.

Among patients with non-HIV–CM, atypical manifestations and non-specific neuroradiological findings due to lack of inflammatory responses are responsible for delays in diagnosis that may contribute

to fatal outcomes^{214,215}. In contrast to guidelines for people living with HIV, there are no specific guidelines for routine serum CrAg screening among patients with other immune suppressive conditions. Patients without HIV are more likely to present with cryptococcal pulmonary involvement and without CNS involvement; thus, lumbar punctures may not be routinely performed in the absence of neurological symptoms^{216,217}. Thus, in immunosuppressed individuals, such as recipients of solid-organ transplants, the requirements and optimal strategy for CrAg screening remain to be defined.

CrAg screening and pre-emptive therapy for CrAg-positive patients living with HIV remain important interventions to decrease the incidence of HIV–CM, especially in high-burden countries. However, programmatic inadequacies, including inaccessibility to CD4⁺ T cell count tests (which are the current entry point for CrAg screening), CrAg tests and antifungal drugs, and suboptimal adherence to guidelines by health-care providers coupled with poor retention of CrAg-positive patients to ensure treatment completion remain significant bottlenecks in decreasing the incidence of HIV–CM and associated mortality^{218,219}.

The most suitable antifungal regimen for pre-emptive therapy remains a subject of research, and a one-size-fits-all approach may not be optimal. In a study evaluating the effectiveness of CrAg screening and pre-emptive fluconazole therapy in addition to ART in patients with AHD, of 152 eligible patients receiving the previously recommend 10-week fluconazole regimen, 7.9% developed breakthrough meningitis²¹⁰. Outcomes at 6 months in individuals with cryptococcal antigenaemia might improve if pre-emptive fluconazole therapy is combined with other antifungal drugs, especially as the current fluconazole is inadequate for those with a CrAg titre of $\geq 1:160$ (refs. 210, 220).

In addition to ART-naïve individuals with HIV, country guidelines should also target ART-experienced persons with suboptimal virological suppression for CrAg screening and pre-emptive therapy, as an increasing proportion of persons with cryptococcosis are ART-experienced²²¹. Serum CrAg-positive persons with neurological symptoms should routinely undergo lumbar puncture to exclude meningitis; however, even when CSF CrAg tests are negative, the mortality among patients with this clinical phenotype remains high, similar to that among patients with cryptococcal meningitis, suggesting that they could benefit from enhanced antifungal therapy^{136,148}.

With a persisting mortality rate between 25% and 30% in trial settings and a 15–20% contribution to HIV-related mortality, the need to expand the pipeline for developing more-potent antifungal drugs to treat cryptococcosis remains significant. Recent data show that a less toxic oral encochleated formulation of amphotericin, MAT2203, given for 2 weeks with flucytosine and continued for four more weeks with fluconazole for treatment resulted in an 18-week survival of 85–90% in patients presenting with a normal baseline GCS²²². Optimizing adjunctive antifungal and host-directed therapy might still be possible. Tamoxifen and sertraline have antifungal activity in vitro and in vivo but were shown to have no impact on cryptococcal clearance or mortality as adjunctive therapies^{223,224}. A small study in 90 patients showed that addition of two doses of short course IFN γ to standard treatment increased the rate of fungal clearance without any increase in adverse events¹¹³. Another study showed a trend to improved combined mycological and clinical success in recipients of recombinant IFN γ -1b¹¹⁴. To optimize cost-effectiveness, biomarkers for selection of patient subgroups most likely to benefit from such therapies are needed.

Novel antifungal therapeutics that have undergone early phase trials include fosmanogepix, and the VT molecules. Fosmanogepix

inhibits the fungal enzyme Gwt1 of the glycosylphosphatidylinositol biosynthesis pathway, thus preventing the biosynthesis of cell wall mannoproteins to compromise cell wall integrity and fungal growth²²⁵. VT-1598 prevents biosynthesis of ergosterol within fungal wall cell membranes by inhibiting fungal rather than mammalian CYP51 (ref. 226). ATI-2307 exhibits equivalent antifungal activity against cryptococcal isolates. As the minimum inhibitory concentrations of ATI-2307 are comparable to those of fluconazole, ATI-2307 could potentially be used in the context of fluconazole resistance²²⁷. Lastly, a new third-generation polyene, SF-001, which is an amphotericin-like glycosylated polyene macrolide²²⁸, is currently in development.

The inclusion of *Cryptococcus* in the 2022 WHO fungal priority pathogen list highlights the contribution of this pathogen to human disease and the need to further invest in research and development of new antifungal therapies²²⁹. Recently adopted point-of-care diagnostics and abbreviated liposomal amphotericin regimens should translate into timely and expanded access to diagnostics and treatment to reduce mortality. The 'End CM Deaths by 2030' strategic framework recommends the priorities to focus on in order to reduce the morbidity and mortality from cryptococcal meningitis²³⁰.

Published online: 09 November 2023

References

- Brizendine, K. D., Baddley, J. W. & Pappas, P. G. Predictors of mortality and differences in clinical features among patients with Cryptococcosis according to immune status. *PLoS ONE* **8**, e60431 (2013).
- Chau, T. T. et al. A prospective descriptive study of cryptococcal meningitis in HIV uninfected patients in Vietnam – high prevalence of *Cryptococcus neoformans* var *grubii* in the absence of underlying disease. *BMC Infect. Dis.* **10**, 199 (2010).
- Chen, J. et al. *Cryptococcus neoformans* strains and infection in apparently immunocompetent patients, China. *Emerg. Infect. Dis.* **14**, 755–762 (2008).
- Freij, J. B. et al. Conservation of intracellular pathogenic strategy among distantly related cryptococcal species. *Infect. Immun.* **86**, e00946–17 (2018).
- Casadevall, A. & Pirofski, L. A. The damage-response framework of microbial pathogenesis. *Nat. Rev. Microbiol.* **1**, 17–24 (2003).
- Baddley, J. W. et al. MSG07: an international cohort study comparing epidemiology and outcomes of patients with *Cryptococcus neoformans* or *Cryptococcus gattii* infections. *Clin. Infect. Dis.* **73**, 1133–1141 (2021).
- Rajasingham, R. et al. The global burden of HIV-associated cryptococcal infection in adults in 2020: a modelling analysis. *Lancet Infect. Dis.* **22**, 1748–1755 (2022).
- Patel, R. K. K. et al. High mortality in HIV-associated cryptococcal meningitis patients treated with amphotericin B-based therapy under routine care conditions in Africa. *Open Forum Infect. Dis.* **5**, ofy267 (2018).
- Finkelstein, A. & Holz, R. Aqueous pores created in thin lipid membranes by the polyene antibiotics nystatin and amphotericin B. *Membranes* **2**, 377–408 (2013).
- Vermes, A., Guchelaar, H. J. & Dankert, J. R. Fluocytosine: a review of its pharmacology, clinical indications, pharmacokinetics, toxicity and drug interactions. *J. Antimicrob. Chemother.* **46**, 171–179 (2000).
- Lee, W. & Lee, D. G. A novel mechanism of fluconazole: fungicidal activity through dose-dependent apoptotic responses in *Candida albicans*. *Microbiology* **164**, 194–204 (2018).
- Molloy, S. F. et al. Antifungal combinations for treatment of cryptococcal meningitis in Africa. *N. Engl. J. Med.* **378**, 1004–1017 (2018).
- Jarvis, J. N. et al. Single-dose liposomal amphotericin b treatment for cryptococcal meningitis. *N. Engl. J. Med.* **366**, 1109–1120 (2022).
- Jarvis, J. N. et al. Cost effectiveness of cryptococcal antigen screening as a strategy to prevent HIV-associated cryptococcal meningitis in South Africa. *PLoS ONE* **8**, e69288 (2013).
- Cogliati, M. Global molecular epidemiology of *Cryptococcus neoformans* and *Cryptococcus gattii*: an atlas of the molecular types. *Scientifica* **2013**, 675213 (2013).
- Montoya, M. C., Magwene, P. M. & Perfect, J. R. Associations between *Cryptococcus* genotypes, phenotypes, and clinical parameters of human disease: a review. *J. Fungi* **7**, 260 (2021).
- Chen, S. C., Meyer, W. & Sorrell, T. C. *Cryptococcus gattii* infections. *Clin. Microbiol. Rev.* **27**, 980–1024 (2014).
- Kidd, S. E. et al. A rare genotype of *Cryptococcus gattii* caused the cryptococcosis outbreak on Vancouver Island (British Columbia, Canada). *Proc. Natl Acad. Sci. USA* **101**, 17258–17263 (2004).
- Fraser, J. A. et al. Same-sex mating and the origin of the Vancouver Island *Cryptococcus gattii* outbreak. *Nature* **437**, 1360–1364 (2005).
- Rajasingham, R. et al. Global burden of disease of HIV-associated cryptococcal meningitis: an updated analysis. *Lancet Infect. Dis.* **17**, 873–881 (2017).
- Ellis, J. et al. The changing epidemiology of HIV-associated adult meningitis, Uganda 2015–2017. *Open Forum Infect. Dis.* **6**, ofz419 (2019).
- Flynn, A. G. et al. Evolving failures in the delivery of human immunodeficiency virus care: lessons from a Ugandan meningitis cohort 2006–2016. *Open Forum Infect. Dis.* **4**, ofx077 (2017).
- Okwir, M. et al. High burden of cryptococcal meningitis among antiretroviral therapy-experienced human immunodeficiency virus-infected patients in Northern Uganda in the era of “test and treat”: implications for cryptococcal screening programs. *Open Forum Infect. Dis.* **9**, ofac004 (2022).
- Chang, B. et al. Timing of antiretroviral therapy prior to diagnosis of cryptococcal meningitis [abstract 2361]. *Open Forum Infect. Dis.* **9** (Suppl. 2), ofac492.168 (2022).
- Kalata, N. et al. Short-term mortality outcomes of HIV-associated cryptococcal meningitis in antiretroviral therapy-naïve and -experienced patients in sub-Saharan Africa. *Open Forum Infect. Dis.* **8**, ofab397 (2021).
- Rhein, J. et al. Detrimental outcomes of unmasking cryptococcal meningitis with recent art initiation. *Open Forum Infect. Dis.* **5**, ofy122 (2018).
- Ford, N. et al. CD4 cell count threshold for cryptococcal antigen screening of HIV-infected individuals: a systematic review and meta-analysis. *Clin. Infect. Dis.* **66**, S152–S159 (2018).
- Jarvis, J. N. et al. Screening for cryptococcal antigenemia in patients accessing an antiretroviral treatment program in South Africa. *Clin. Infect. Dis.* **48**, 856–862 (2009).
- French, N. et al. Cryptococcal infection in a cohort of HIV-1-infected Ugandan adults. *AIDS* **16**, 1031–1038 (2002).
- Sungkanupraph, S. et al. Cryptococcal immune reconstitution inflammatory syndrome after antiretroviral therapy in AIDS patients with cryptococcal meningitis: a prospective multicenter study. *Clin. Infect. Dis.* **49**, 931–934 (2009).
- Shelburne, S. A. 3rd et al. The role of immune reconstitution inflammatory syndrome in AIDS-related *Cryptococcus neoformans* disease in the era of highly active antiretroviral therapy. *Clin. Infect. Dis.* **40**, 1049–1052 (2005).
- Kambugu, A. et al. Outcomes of cryptococcal meningitis in Uganda before and after the availability of highly active antiretroviral therapy. *Clin. Infect. Dis.* **46**, 1694–1701 (2008).
- Lortholary, O. et al. Incidence and risk factors of immune reconstitution inflammatory syndrome complicating HIV-associated cryptococcosis in France. *AIDS* **19**, 1043–1049 (2005).
- Boulware, D. R. et al. Timing of antiretroviral therapy after diagnosis of cryptococcal meningitis. *N. Engl. J. Med.* **370**, 2487–2498 (2014).
- Zhao, T. et al. The effect of early vs. deferred antiretroviral therapy initiation in HIV-infected patients with cryptococcal meningitis: a multicenter prospective randomized controlled analysis in China. *Front. Med.* **8**, 771981 (2021).
- Sereti, I. et al. Prospective international study of incidence and predictors of immune reconstitution inflammatory syndrome and death in people with HIV and severe lymphopenia. *Clin. Infect. Dis.* **27**, 652–660 (2020).
- Han, X. et al. A nomogram for predicting paradoxical immune reconstitution inflammatory syndrome associated with cryptococcal meningitis among HIV-infected individuals in China. *AIDS Res. Ther.* **19**, 20 (2022).
- Brienze, V. M. S., André, J. C., Liso, E. & Vlasova-St Louis, I. Cryptococcal immune reconstitution inflammatory syndrome: from blood and cerebrospinal fluid biomarkers to treatment approaches. *Life* **11**, 95 (2020).
- Jarvis, J. N. et al. Determinants of mortality in a combined cohort of 501 patients with HIV-associated cryptococcal meningitis: implications for improving outcomes. *Clin. Infect. Dis.* **58**, 736–745 (2014).
- Pasquier, E. et al. Long-term mortality and disability in cryptococcal meningitis: a systematic literature review. *Clin. Infect. Dis.* **66**, 1122–1132 (2018).
- Boulware, D. R. et al. Clinical features and serum biomarkers in HIV immune reconstitution inflammatory syndrome after cryptococcal meningitis: a prospective cohort study. *PLoS Med.* **7**, e1000384 (2010).
- Chaiwarith, R., Vongsanim, S. & Supparatpinoy, K. Cryptococcal meningitis in HIV-infected patients at Chiang Mai University Hospital: a retrospective study. *Southeast. Asian J. Trop. Med. Public Health* **45**, 636–646 (2014).
- Day, J. N. et al. Combination antifungal therapy for cryptococcal meningitis. *N. Engl. J. Med.* **368**, 1291–1302 (2013).
- Lortholary, O. et al. Long-term outcome of AIDS-associated cryptococcosis in the era of combination antiretroviral therapy. *AIDS* **20**, 2183–2191 (2006).
- Vidal, J. E. et al. HIV-associated cryptococcal meningitis patients treated with amphotericin B deoxycholate plus flucytosine under routine care conditions in a referral center in São Paulo, Brazil. *Mycopathologia* **186**, 93–102 (2021).
- Longley, N. et al. Cryptococcal antigen screening in patients initiating ART in South Africa: a prospective cohort study. *Clin. Infect. Dis.* **62**, 581–587 (2016).
- Mfinanga, S. et al. Cryptococcal meningitis screening and community-based early adherence support in people with advanced HIV infection starting antiretroviral therapy in Tanzania and Zambia: an open-label, randomised controlled trial. *Lancet* **385**, 2173–2182 (2015).
- Wake, R. M. et al. Cryptococcal-related mortality despite fluconazole preemptive treatment in a cryptococcal antigen screen-and-treat program. *Clin. Infect. Dis.* **70**, 1683–1690 (2020).
- Rajasingham, R. et al. Cryptococcal meningitis diagnostics and screening in the era of point-of-care laboratory testing. *J. Clin. Microbiol.* **57**, e01238-18 (2019).

50. Bicanic, T. et al. Independent association between rate of clearance of infection and clinical outcome of HIV-associated cryptococcal meningitis: analysis of a combined cohort of 262 patients. *Clin. Infect. Dis.* **49**, 702–709 (2009).
51. Pullen, M. F. et al. Cerebrospinal fluid early fungicidal activity as a surrogate endpoint for cryptococcal meningitis survival in clinical trials. *Clin. Infect. Dis.* **71**, e45–e49 (2020).
52. Coussement, J. et al. Current epidemiology and clinical features of *Cryptococcus* infection in patients without HIV infection: a multicentre study in 46 hospitals from Australia and New Zealand. *Clin. Infect. Dis.* **77**, 976–986 (2023).
53. Pappas, P. G. et al. Cryptococcosis in human immunodeficiency virus-negative patients in the era of effective azole therapy. *Clin. Infect. Dis.* **33**, 690–699 (2001).
54. Rosen, L. B. et al. Anti-GM-CSF autoantibodies in patients with cryptococcal meningitis. *J. Immunol.* **190**, 3959–3966 (2013).
55. Kuo, C. Y. et al. Disseminated cryptococcosis due to anti-granulocyte-macrophage colony-stimulating factor autoantibodies in the absence of pulmonary alveolar proteinosis. *J. Clin. Immunol.* **37**, 143–152 (2017).
56. Arango-Franco, C. A. et al. Anti-GM-CSF neutralizing autoantibodies in Colombian patients with disseminated cryptococcosis. *J. Clin. Immunol.* **43**, 921–932 (2023).
57. Ahmad, D. S., Esmadi, M. & Steinmann, W. C. Idiopathic CD4 lymphocytopenia: spectrum of opportunistic infections, malignancies, and autoimmune diseases. *Avicenna J. Med.* **3**, 37–47 (2013).
58. Browne, S. K. et al. Adult-onset immunodeficiency in Thailand and Taiwan. *N. Engl. J. Med.* **367**, 725–734 (2012).
59. Liu, J. et al. Analysis of the association of HLA subtypes with cryptococcal meningitis in HIV-negative immunocompetent patients. *Future Microbiol.* **17**, 1231–1240 (2022).
60. Wu, U. I. et al. Incorrect diagnoses in patients with neutralizing anti-interferon- γ -autoantibodies. *Clin. Microbiol. Infect.* **26**, 1684.e1–1684.e6 (2020).
61. Su, X. H. et al. Comparison of features and outcomes between HIV-negative patients with *Cryptococcus gattii* meningitis and *Cryptococcus neoformans* meningitis in South China. *Mycoses* **65**, 887–896 (2022).
62. Day, J. N. et al. Comparative genomics of *Cryptococcus neoformans* var. *grubii* associated with meningitis in HIV infected and uninfected patients in Vietnam. *PLoS Negl. Trop. Dis.* **11**, e0005628 (2017).
63. Thanh, L. T. et al. Assessing the virulence of *Cryptococcus neoformans* causing meningitis in HIV infected and uninfected patients in Vietnam. *Med. Mycol.* **58**, 1149–1161 (2020).
64. Yang, D. H. et al. *Cryptococcus gattii* species complex as an opportunistic pathogen: underlying medical conditions associated with the infection. *mBio* **12**, e0270821 (2021).
65. Saijo, T. et al. Anti-granulocyte-macrophage colony-stimulating factor autoantibodies are a risk factor for central nervous system infection by *Cryptococcus gattii* in otherwise immunocompetent patients. *mBio* **5**, e00912-14 (2014).
66. Barcenas-Morales, G., Cortes-Acevedo, P. & Doffinger, R. Anticytokine autoantibodies leading to infection: early recognition, diagnosis and treatment options. *Curr. Opin. Infect. Dis.* **32**, 330–336 (2019).
67. Liao, C. H. et al. Different presentations and outcomes between HIV-infected and HIV-uninfected patients with cryptococcal meningitis. *J. Microbiol. Immunol. Infect.* **45**, 296–304 (2012).
68. Pyrgos, V., Seitz, A. E., Steiner, C. A., Prevots, D. R. & Williamson, P. R. Epidemiology of cryptococcal meningitis in the US: 1997–2009. *PLoS ONE* **8**, e52669 (2013).
69. Marr, K. A. et al. A multicenter, longitudinal cohort study of cryptococcosis in human immunodeficiency virus-negative people in the United States. *Clin. Infect. Dis.* **70**, 252–261 (2020).
70. Levitz, S. M. The ecology of *Cryptococcus neoformans* and the epidemiology of cryptococcosis. *Rev. Infect. Dis.* **13**, 1163–1169 (1991).
71. Bartlett, K. H., Kidd, S. E. & Kronstad, J. W. The emergence of *Cryptococcus gattii* in British Columbia and the Pacific Northwest. *Curr. Infect. Dis. Rep.* **10**, 58–65 (2008).
72. Datta, K. et al. Spread of *Cryptococcus gattii* into Pacific Northwest region of the United States. *Emerg. Infect. Dis.* **15**, 1185–1191 (2009).
73. Guhani, H. C. et al. Isolation of *Cryptococcus gattii* and *Cryptococcus neoformans* var. *grubii* from the flowers and bark of eucalyptus trees in India. *Med. Mycol.* **43**, 565–569 (2005).
74. Kozubowski, L. & Heitman, J. Profiling a killer, the development of *Cryptococcus neoformans*. *FEMS Microbiol. Rev.* **36**, 78–94 (2012).
75. Desnos-Ollivier, M. et al. Mixed infections and in vivo evolution in the human fungal pathogen *Cryptococcus neoformans*. *mBio* **1**, e00091-10 (2010).
76. Chang, Y. C. et al. Cryptococcal yeast cells invade the central nervous system via transcellular penetration of the blood-brain barrier. *Infect. Immun.* **72**, 4985–4995 (2004).
77. George, I. A., Santos, C. A. Q., Olsen, M. A. & Powderly, W. G. Epidemiology of cryptococcosis and cryptococcal meningitis in a large retrospective cohort of patients after solid organ transplantation. *Open Forum Infect. Dis.* **4**, ofx004 (2017).
78. Kapoor, A. et al. Cryptococcal meningitis in renal transplant patients associated with environmental exposure. *Transpl. Infect. Dis.* **1**, 213–217 (1999).
79. Osterholzer, J. J. et al. Role of dendritic cells and alveolar macrophages in regulating early host defense against pulmonary infection with *Cryptococcus neoformans*. *Infect. Immun.* **77**, 3749–3758 (2009).
80. Biondo, C. et al. MyD88 and TLR2, but not TLR4, are required for host defense against *Cryptococcus neoformans*. *Eur. J. Immunol.* **35**, 870–878 (2005).
81. Cross, C. E. & Bancroft, G. J. Ingestion of acapsular *Cryptococcus neoformans* occurs via mannose and beta-glucan receptors, resulting in cytokine production and increased phagocytosis of the encapsulated form. *Infect. Immun.* **63**, 2604–2611 (1995).
82. Kozel, T. R., Frommer, G. S., Guerlain, A. S., Highison, B. A. & Highison, G. J. Strain variation in phagocytosis of *Cryptococcus neoformans*: dissociation of susceptibility to phagocytosis from activation and binding of opsonic fragments of C3. *Infect. Immun.* **56**, 2794–2800 (1988).
83. Casadevall, A. et al. The capsule of *Cryptococcus neoformans*. *Virulence* **10**, 822–831 (2019).
84. Wozniak, K. L. Interactions of *Cryptococcus* with dendritic cells. *J. Fungi* **4**, 36 (2018).
85. Chen, G. H. et al. The gamma interferon receptor is required for the protective pulmonary inflammatory response to *Cryptococcus neoformans*. *Infect. Immun.* **73**, 1788–1796 (2005).
86. George, I. A., Spec, A., Powderly, W. G. & Santos, C. A. Q. Comparative epidemiology and outcomes of human immunodeficiency virus (HIV), Non-HIV non-transplant, and solid organ transplant associated cryptococcosis: a population-based study. *Clin. Infect. Dis.* **66**, 608–611 (2018).
87. Kiertburanakul, S., Wirojtanugoon, S., Prachartam, R. & Sungkanuparph, S. Cryptococcosis in human immunodeficiency virus-negative patients. *Int. J. Infect. Dis.* **10**, 72–78 (2006).
88. Lin, Y. Y., Shiau, S. & Fang, C. T. Risk factors for invasive *Cryptococcus neoformans* diseases: a case-control study. *PLoS ONE* **10**, e0119090 (2015).
89. Costa, M. L., Souza, J. P., Oliveira Neto, A. F. & Pinto, E. S. J. L. Cryptococcal meningitis in HIV negative pregnant women: case report and review of literature. *Rev. Inst. Med. Trop. Sao Paulo* **51**, 289–294 (2009).
90. Wipasa, J. et al. Characterization of anti-interferon- γ antibodies in HIV-negative immunodeficient patients infected with unusual intracellular microorganisms. *Exp. Biol. Med.* **243**, 621–626 (2018).
91. Golde, D. W., Territo, M., Finley, T. N. & Cline, M. J. Defective lung macrophages in pulmonary alveolar proteinosis. *Ann. Intern. Med.* **85**, 304–309 (1976).
92. McClelland, E. E., Bernhardt, P. & Casadevall, A. Estimating the relative contributions of virulence factors for pathogenic microbes. *Infect. Immun.* **74**, 1500–1504 (2006).
93. Zaragoza, O. et al. Capsule enlargement in *Cryptococcus neoformans* confers resistance to oxidative stress suggesting a mechanism for intracellular survival. *Cell Microbiol.* **10**, 2043–2057 (2008).
94. Denham, S. T. et al. Regulated release of cryptococcal polysaccharide drives virulence and suppresses immune cell infiltration into the central nervous system. *Infect. Immun.* **86**, e00662-17 (2018).
95. Rodrigues, J. et al. Lack of chitin synthase genes impacts capsular architecture and cellular physiology in *Cryptococcus neoformans*. *Cell Surf.* **2**, 14–23 (2018).
96. Baker, L. G., Specht, C. A., Donlin, M. J. & Lodge, J. K. Chitosan, the deacetylated form of chitin, is necessary for cell wall integrity in *Cryptococcus neoformans*. *Eukaryot. Cell* **6**, 855–867 (2007).
97. Banks, I. R. et al. A chitin synthase and its regulator protein are critical for chitosan production and growth of the fungal pathogen *Cryptococcus neoformans*. *Eukaryot. Cell* **4**, 1902–1912 (2005).
98. Kwon-Chung, K. J., Polacheck, I. & Popkin, T. J. Melanin-lacking mutants of *Cryptococcus neoformans* and their virulence for mice. *J. Bacteriol.* **150**, 1414–1421 (1982).
99. Williamson, P. R. Laccase and melanin in the pathogenesis of *Cryptococcus neoformans*. *Front. Biosci.* **2**, e99–e107 (1997).
100. Shea, J. M., Kechichian, T. B., Luberto, C. & Del Poeta, M. The cryptococcal enzyme inositol phosphophingolipid-phospholipase C confers resistance to the antifungal effects of macrophages and promotes fungal dissemination to the central nervous system. *Infect. Immun.* **74**, 5977–5988 (2006).
101. Hamed, M. F. et al. Phospholipase B is critical for *Cryptococcus neoformans* survival in the central nervous system. *mBio* **14**, e0264022 (2023).
102. Evans, R. J. et al. Cryptococcal phospholipase B1 is required for intracellular proliferation and control of titan cell morphology during macrophage infection. *Infect. Immun.* **83**, 1296–1304 (2015).
103. Ganendren, R., Carter, E., Sorrell, T., Widmer, F. & Wright, L. Phospholipase B activity enhances adhesion of *Cryptococcus neoformans* to a human lung epithelial cell line. *Microbes Infect.* **8**, 1006–1015 (2006).
104. Santangelo, R. T. et al. Biochemical and functional characterisation of secreted phospholipase activities from *Cryptococcus neoformans* in their naturally occurring state. *J. Med. Microbiol.* **48**, 731–740 (1999).
105. Fu, M. S. et al. *Cryptococcus neoformans* urease affects the outcome of intracellular pathogenesis by modulating phagolysosomal pH. *PLoS Pathog.* **14**, e1007144 (2018).
106. Singh, A. et al. Factors required for activation of urease as a virulence determinant in *Cryptococcus neoformans*. *mBio* **4**, e00220-13 (2013).
107. Baker, R. P. & Casadevall, A. Reciprocal modulation of ammonia and melanin production has implications for cryptococcal virulence. *Nat. Commun.* **14**, 849 (2023).
108. Charlier, C. et al. Evidence of a role for monocytes in dissemination and brain invasion by *Cryptococcus neoformans*. *Infect. Immun.* **77**, 120–127 (2009).
109. Sun, D. & Shi, M. Neutrophil swarming toward *Cryptococcus neoformans* is mediated by complement and leukotriene B₄. *Biochem. Biophys. Res. Commun.* **477**, 945–951 (2016).
110. Leopold Wager, C. M., Hole, C. R., Wozniak, K. L., Olszewski, M. A. & Wormley, F. L. Jr. STAT1 signaling is essential for protection against *Cryptococcus neoformans* infection in mice. *J. Immunol.* **193**, 4060–4071 (2014).
111. Heung, L. J. & Hohl, T. M. Inflammatory monocytes are detrimental to the host immune response during acute infection with *Cryptococcus neoformans*. *PLoS Pathog.* **15**, e1007627 (2019).

112. Jarvis, J. N. et al. The phenotype of the *Cryptococcus*-specific CD4⁺ memory T-cell response is associated with disease severity and outcome in HIV-associated cryptococcal meningitis. *J. Infect. Dis.* **207**, 1817–1828 (2013).
113. Jarvis, J. N. et al. Adjunctive interferon- γ immunotherapy for the treatment of HIV-associated cryptococcal meningitis: a randomized controlled trial. *AIDS* **26**, 1105–1113 (2012).
114. Pappas, P. G. et al. Recombinant interferon- γ 1b as adjunctive therapy for AIDS-related acute cryptococcal meningitis. *J. Infect. Dis.* **189**, 2185–2191 (2004).
115. Lee, S. C., Kress, Y., Zhao, M. L., Dickson, D. W. & Casadevall, A. *Cryptococcus neoformans* survive and replicate in human microglia. *Lab. Invest.* **73**, 871–879 (1995).
116. Lee, S. C., Kress, Y., Dickson, D. W. & Casadevall, A. Human microglia mediate anti-*Cryptococcus neoformans* activity in the presence of specific antibody. *J. Neuroimmunol.* **62**, 43–52 (1995).
117. Koutsouras, G. W., Ramos, R. L. & Martinez, L. R. Role of microglia in fungal infections of the central nervous system. *Virulence* **8**, 705–718 (2017).
118. Neal, L. M. et al. CD4⁺ T cells orchestrate lethal immune pathology despite fungal clearance during *Cryptococcus neoformans* meningoencephalitis. *mBio* **8**, e01415-17 (2017).
119. Aguirre, K. M. & Johnson, L. L. A role for B cells in resistance to *Cryptococcus neoformans* in mice. *Infect. Immun.* **65**, 525–530 (1997).
120. Okurut, S. et al. B cell compartmentalization in blood and cerebrospinal fluid of HIV-infected Ugandans with cryptococcal meningitis. *Infect. Immun.* **88**, e00779-19 (2020).
121. Yoon, H. A. et al. Association between plasma antibody responses and risk for *Cryptococcus*-associated immune reconstitution inflammatory syndrome. *J. Infect. Dis.* **219**, 420–428 (2019).
122. Haddow, L. J. et al. Cryptococcal immune reconstitution inflammatory syndrome in HIV-1-infected individuals: proposed clinical case definitions. *Lancet Infect. Dis.* **10**, 791–802 (2010).
123. Bonham, S., Mehta, D. B., Bohjanen, P. R. & Boulware, D. R. Biomarkers of HIV immune reconstitution inflammatory syndrome. *Biomark. Med.* **2**, 349–361 (2008).
124. Boulware, D. R. et al. Paucity of initial cerebrospinal fluid inflammation in cryptococcal meningitis is associated with subsequent immune reconstitution inflammatory syndrome. *J. Infect. Dis.* **202**, 962–970 (2010).
125. Scriven, J. E. et al. The CSF immune response in HIV-1-associated cryptococcal meningitis: macrophage activation, correlates of disease severity, and effect of antiretroviral therapy. *J. Acquir. Immune Defic. Syndr.* **75**, 299–307 (2017).
126. Scriven, J. E. et al. Early ART after cryptococcal meningitis is associated with cerebrospinal fluid pleocytosis and macrophage activation in a multisite randomized trial. *J. Infect. Dis.* **212**, 769–778 (2015).
127. Chang, C. C. et al. Clinical and mycological predictors of cryptococcosis-associated immune reconstitution inflammatory syndrome. *AIDS* **27**, 2089–2099 (2013).
128. Boulware, D. R. et al. Higher levels of CRP, D-dimer, IL-6, and hyaluronate before initiation of antiretroviral therapy (ART) are associated with increased risk of AIDS or death. *J. Infect. Dis.* **203**, 1637–1646 (2011).
129. Boulware, D. R. et al. Multisite validation of cryptococcal antigen lateral flow assay and quantification by laser thermal contrast. *Emerg. Infect. Dis.* **20**, 45–53 (2014).
130. Hansen, J. et al. Large-scale evaluation of the immuno-mycology lateral flow and enzyme-linked immunoassays for detection of cryptococcal antigen in serum and cerebrospinal fluid. *Clin. Vaccin. Immunol.* **20**, 52–55 (2013).
131. Percival, A., Thorkildsen, P. & Kozel, T. R. Monoclonal antibodies specific for immunoreactive epitopes of glucuronoxylomannan, the major capsular polysaccharide of *Cryptococcus neoformans*, reduce serotype bias in an immunoassay for cryptococcal antigen. *Clin. Vaccin. Immunol.* **18**, 1292–1296 (2011).
132. Bridge, S. et al. Evaluation of the biofire(R) filmarray(R) meningitis/encephalitis panel in an adult and pediatric Ugandan population. *J. Mycol. Med.* **31**, 101170 (2021).
133. Skipper, C. et al. Evaluation of serum cryptococcal antigen testing using two novel semiquantitative lateral flow assays in persons with cryptococcal antigenemia. *J. Clin. Microbiol.* **58**, e02046-19 (2020).
134. Kwizera, R. et al. Evaluation of the Dynamiker cryptococcal antigen lateral flow assay for the diagnosis of HIV-associated cryptococcosis. *J. Clin. Microbiol.* **59**, e02421-20 (2021).
135. Mpoza, E. et al. Evaluation of a point-of-care immunoassay test kit 'StrongStep' for cryptococcal antigen detection. *PLoS ONE* **13**, e0190652 (2018).
136. Ssebambulidde, K. et al. Symptomatic cryptococcal antigenemia presenting as early cryptococcal meningitis with negative cerebral spinal fluid analysis. *Clin. Infect. Dis.* **68**, 2094–2098 (2018).
137. Anjum, S. H. et al. Neuroimaging of cryptococcal meningitis in patients without human immunodeficiency virus: data from a multi-center cohort study. *J. Fungi* **9**, 594 (2023).
138. Chen, S. et al. Epidemiology and host- and variety-dependent characteristics of infection due to *Cryptococcus neoformans* in Australia and New Zealand. Australasian Cryptococcal study group. *Clin. Infect. Dis.* **31**, 499–508 (2000).
139. Perfect, J. R. et al. Clinical practice guidelines for the management of cryptococcal disease: 2010 update by the Infectious Diseases Society of America. *Clin. Infect. Dis.* **50**, 291–322 (2010).
140. Bahr, N. C. et al. Recurrence of symptoms following cryptococcal meningitis: characterizing a diagnostic conundrum with multiple etiologies. *Clin. Infect. Dis.* **76**, 1080–1087 (2023).
141. Musubire, A. K., Boulware, D. R., Mehta, D. B. & Rhein, J. Diagnosis and management of cryptococcal relapse. *J. AIDS Clin. Res. Suppl.* **3**, S3-003 (2013).
142. Rhein, J. et al. Diagnostic performance of a multiplex PCR assay for meningitis in an HIV-infected population in Uganda. *Diagn. Microbiol. Infect. Dis.* **84**, 268–273 (2016).
143. Mbangiwa, T. et al. *Cryptococcus* qPCR assays: the future for routine mycology labs and clinical trials dealing with cryptococcosis [abstract S1.4d]. *Med. Mycol.* **60** (Suppl. 1), myac072S14d (2022).
144. Del Poeta, M., Wormley, F. L. Jr. & Lin, X. Host populations, challenges, and commercialization of cryptococcal vaccines. *PLoS Pathog.* **19**, e1011115 (2023).
145. World Health Organization. Guidelines for diagnosing, preventing and managing cryptococcal disease among adults, adolescents and children living with HIV. *World Health Organization* <https://www.who.int/publications/i/item/9789240052178> (2022).
146. Mehta, D. B. et al. Cost-effectiveness of serum cryptococcal antigen screening to prevent deaths among HIV-infected persons with a CD4⁺ cell count \leq 100 cells/ μ L who start HIV therapy in resource-limited settings. *Clin. Infect. Dis.* **51**, 448–455 (2010).
147. World Health Organization. Rapid advice: diagnosis, prevention and management of cryptococcal disease in HIV-infected adults, adolescents and children. *World Health Organization* www.who.int/hiv/pub/cryptococcal_disease2011 (2011).
148. Wake, R. M. et al. High cryptococcal antigen titers in blood are predictive of subclinical cryptococcal meningitis among human immunodeficiency virus-infected patients. *Clin. Infect. Dis.* **66**, 686–692 (2018).
149. Rajasingham, R. & Boulware, D. R. Cryptococcal antigen screening and preemptive treatment – how can we improve survival? *Clin. Infect. Dis.* **70**, 1691–1694 (2020).
150. Rutakingirwa, M. K. et al. Tuberculosis in HIV-associated cryptococcal meningitis is associated with an increased risk of death. *J. Clin. Med.* **9**, 781 (2020).
151. Skipper, C. et al. Cytomegalovirus viremia associated with increased mortality in cryptococcal meningitis in sub-Saharan Africa. *Clin. Infect. Dis.* **71**, 525–531 (2020).
152. Skipper, C. P. et al. Cytomegalovirus viremia as a risk factor for mortality in HIV-associated cryptococcal and tuberculous meningitis. *Int. J. Infect. Dis.* **122**, 785–792 (2022).
153. World Health Organization. Guideline for managing advanced HIV disease and the timing for initiating antiretroviral therapy. *World Health Organization* <http://www.who.int/hiv/pub/guidelines/advanced-HIV-disease/en/> (2017).
154. World Health Organization. WHO consolidated guidelines on tuberculosis: module 3: diagnosis: rapid diagnostics for tuberculosis detection, 2021 update. *World Health Organization* <https://www.who.int/publications/i/item/9789240029415> (2021).
155. Rajasingham, R. et al. Nosocomial drug-resistant bacteremia in 2 cohorts with cryptococcal meningitis, Africa. *Emerg. Infect. Dis.* **20**, 722–724 (2014).
156. Moore, C. C. et al. Etiology of sepsis in Uganda using a quantitative polymerase chain reaction-based TaqMan Array Card. *Clin. Infect. Dis.* **68**, 266–272 (2019).
157. Hakim, J. et al. Enhanced prophylaxis plus antiretroviral therapy for advanced HIV infection in Africa. *N. Engl. J. Med.* **377**, 233–245 (2017).
158. Einsele, H. et al. Risk factors for treatment failures in patients receiving PCR-based preemptive therapy for CMV infection. *Bone Marrow Transplant.* **25**, 757–763 (2000).
159. Rose, D. N. & Sacks, H. S. Cost-effectiveness of cytomegalovirus (CMV) disease prevention in patients with AIDS: oral ganciclovir and CMV polymerase chain reaction testing. *AIDS* **11**, 883–887 (1997).
160. Wohl, D. A. et al. Low rate of CMV end-organ disease in HIV-infected patients despite low CD4⁺ cell counts and CMV viremia: results of ACTG protocol A5030. *HIV Clin. Trials* **10**, 143–152 (2009).
161. Skipper, C. P. & Schleiss, M. R. Cytomegalovirus viremia and advanced HIV disease: is there an argument for anti-CMV treatment. *Expert. Rev. Anti Infect. Ther.* **21**, 227–233 (2023).
162. Panel on Guidelines for the Prevention and Treatment of Opportunistic Infections in Adults and Adolescents with HIV. Guidelines for the prevention and treatment of opportunistic infections in HIV-infected adults and adolescents: recommendations from the Centers for Disease Control and Prevention, the National Institutes of Health, and the HIV Medicine Association of the Infectious Diseases Society of America. *clinicalinfo.hiv.gov* <https://clinicalinfo.hiv.gov/en/guidelines/adult-and-adolescent-opportunistic-infection/cryptococcosis> (2022).
163. Bicanic, T. et al. Toxicity of amphotericin B deoxycholate-based induction therapy in patients with HIV-associated cryptococcal meningitis. *Antimicrob. Agents Chemother.* **59**, 7224–7231 (2015).
164. Bahr, N. C. et al. Standardized electrolyte supplementation and fluid management improves survival during amphotericin therapy for cryptococcal meningitis in resource-limited settings. *Open Forum Infect. Dis.* **1**, ofu070 (2014).
165. Schutz, C. et al. Acute kidney injury and urinary biomarkers in human immunodeficiency virus-associated cryptococcal meningitis. *Open Forum Infect. Dis.* **4**, ofx127 (2017).
166. Muzoor, C. K. et al. Short course amphotericin B with high dose fluconazole for HIV-associated cryptococcal meningitis. *J. Infect.* **64**, 76–81 (2012).
167. Rajasingham, R., Rolfes, M. A., Birkenkamp, K. E., Mehta, D. B. & Boulware, D. R. Cryptococcal meningitis treatment strategies in resource-limited settings: a cost-effectiveness analysis. *PLoS Med.* **9**, e1001316 (2012).
168. World Health Organization. Guidelines for the diagnosis, prevention, and management of cryptococcal disease in HIV-infected adults, adolescents and children. *World Health Organization* <https://apps.who.int/iris/bitstream/handle/10665/260399/9789241550277-eng.pdf> (2018).
169. Stone, N. R., Bicanic, T., Salim, R. & Hope, W. Liposomal amphotericin B (AmBisome((R))): a review of the pharmacokinetics, pharmacodynamics, clinical experience and future directions. *Drugs* **76**, 485–500 (2016).

170. Lawrence, D. S. et al. Cost-effectiveness of single, high-dose, liposomal amphotericin regimen for HIV-associated cryptococcal meningitis in five countries in sub-Saharan Africa: an economic analysis of the AMBITION-cm trial. *Lancet Glob. Health* **10**, e1845–e1854 (2022).
171. Lawrence, D. S. et al. The acceptability of the AMBITION-cm treatment regimen for HIV-associated cryptococcal meningitis: findings from a qualitative methods study of participants and researchers in Botswana and Uganda. *PLoS Negl. Trop. Dis.* **16**, e010825 (2022).
172. Harrison, T. S. et al. How applicable is the single-dose AMBITION regimen for human immunodeficiency virus-associated cryptococcal meningitis to high-income settings? *Clin. Infect. Dis.* **76**, 944–949 (2023).
173. Panackal, A. A., Marr, K. A. & Williamson, P. R. Dexamethasone in cryptococcal meningitis. *N. Engl. J. Med.* **375**, 188 (2016).
174. Beardsley, J. et al. Adjunctive dexamethasone in HIV-associated cryptococcal meningitis. *N. Engl. J. Med.* **374**, 542–554 (2016).
175. Govender, N. P. et al. Southern African HIV Clinicians Society guideline for the prevention, diagnosis and management of cryptococcal disease among HIV-infected persons: 2019 update. *South. Afr. J. HIV Med.* **20**, 1030 (2019).
176. Beyene, T. et al. Inadequacy of high-dose fluconazole monotherapy among cerebrospinal fluid cryptococcal antigen (CrAg)-positive human immunodeficiency virus-infected persons in an Ethiopian CrAg screening program. *Clin. Infect. Dis.* **65**, 2126–2129 (2017).
177. US National Library of Medicine. *ClinicalTrials.gov* <https://clinicaltrials.gov/study/NCT03945448> (2023).
178. ISRCTN registry. *isrctn.com* <https://www.isrctn.com/ISRCTN30579828> (2023).
179. Zolopa, A. et al. Early antiretroviral therapy reduces AIDS progression/death in individuals with acute opportunistic infections: a multicenter randomized strategy trial. *PLoS ONE* **4**, e5575 (2009).
180. Makadzange, A. T. et al. Early versus delayed initiation of antiretroviral therapy for concurrent HIV infection and cryptococcal meningitis in sub-Saharan Africa. *Clin. Infect. Dis.* **50**, 1532–1538 (2010).
181. Bisson, G. P. et al. Early versus delayed antiretroviral therapy and cerebrospinal fluid fungal clearance in adults with HIV and cryptococcal meningitis. *Clin. Infect. Dis.* **56**, 1165–1173 (2013).
182. Alufandika, M. et al. A pragmatic approach to managing antiretroviral therapy-experienced patients diagnosed with HIV-associated cryptococcal meningitis: impact of antiretroviral therapy adherence and duration. *AIDS* **34**, 1425–1428 (2020).
183. Boulware, D. R. & Jarvis, J. N. Timing of antiretroviral therapy in cryptococcal meningitis: what we can (and cannot) learn from observational data. *Clin. Infect. Dis.* **77**, 74–76 (2023).
184. Beardsley, J. et al. Do Intracerebral cytokine responses explain the harmful effects of dexamethasone in human immunodeficiency virus-associated cryptococcal meningitis? *Clin. Infect. Dis.* **68**, 1494–1501 (2018).
185. Brunel, A. S. et al. Thalidomide for steroid-dependent immune reconstitution inflammatory syndromes during AIDS. *AIDS* **26**, 2110–2112 (2012).
186. Gaube, G. et al. Treatment with adalimumab for severe immune reconstitution inflammatory syndrome in an HIV-infected patient presenting with cryptococcal meningitis. *Med. Mal. Infect.* **46**, 154–156 (2016).
187. Ssebabulidde, K. et al. Treatment recommendations for non-HIV associated cryptococcal meningoencephalitis including management of post-infectious inflammatory response syndrome. *Front. Neurol.* **13**, 994396 (2022).
188. Anjum, S. et al. Outcomes in previously healthy cryptococcal meningoencephalitis patients treated with pulse taper corticosteroids for post-infectious inflammatory syndrome. *Clin. Infect. Dis.* **73**, e2789–e2798 (2021).
189. Tugume, L. et al. Prognostic implications of baseline anaemia and changes in haemoglobin concentrations with amphotericin B therapy for cryptococcal meningitis. *HIV Med.* **18**, 13–20 (2017).
190. Tugume, L. et al. Association of hyponatremia on mortality in cryptococcal meningitis: a prospective cohort. *Open Forum Infect. Dis.* **9**, ofac301 (2022).
191. Lofgren, S. et al. Differences in immunologic factors among patients presenting with altered mental status during cryptococcal meningitis. *J. Infect. Dis.* **215**, 693–697 (2017).
192. Pastick, K. A. et al. Seizures in human immunodeficiency virus-associated cryptococcal meningitis: predictors and outcomes. *Open Forum Infect. Dis.* **6**, ofz478 (2019).
193. Abassi, M. et al. Cerebrospinal fluid lactate as a prognostic marker of disease severity and mortality in cryptococcal meningitis. *Clin. Infect. Dis.* **73**, e3077–e3082 (2021).
194. Rolfes, M. A. et al. The effect of therapeutic lumbar punctures on acute mortality from cryptococcal meningitis. *Clin. Infect. Dis.* **59**, 1607–1614 (2014).
195. Bicanic, T. et al. Relationship of cerebrospinal fluid pressure, fungal burden and outcome in patients with cryptococcal meningitis undergoing serial lumbar punctures. *AIDS* **23**, 701–706 (2009).
196. Kagimu, E. et al. Therapeutic lumbar punctures in human immunodeficiency virus-associated cryptococcal meningitis: should opening pressure direct management? *Open Forum Infect. Dis.* **9**, ofac416 (2022).
197. Kitonsa, J. et al. Factors affecting mortality among HIV positive patients two years after completing recommended therapy for cryptococcal meningitis in Uganda. *PLoS ONE* **14**, e0210287 (2019).
198. Kitonsa, J. et al. Quality of life and associated factors among HIV positive patients after completion of treatment for cryptococcal meningitis. *PLoS Negl. Trop. Dis.* **15**, e0008983 (2021).
199. Dean, O. et al. Quality of life of HIV-negative, previously healthy individuals following cryptococcal meningoencephalitis. *Sci. Rep.* **11**, 3673 (2021).
200. Krishnamoorthy, A., Joel, A. & Abhilash, K. P. Cryptococcal meningitis with multiple cranial nerves palsies: a review of literature. *J. Glob. Infect. Dis.* **7**, 123–124 (2015).
201. Mohan, S., Ahmed, S. I., Alao, O. A. & Schliep, T. C. A case of AIDS associated cryptococcal meningitis with multiple cranial nerve neuropathies. *Clin. Neurol. Neurosurg.* **108**, 610–613 (2006).
202. Rival, G. et al. Bilateral cranial nerve VI palsies in cryptococcal meningitis, HIV, and syphilis: a case report. *Clin. Pract. Cases Emerg. Med.* **5**, 515–518 (2021).
203. Duggan, J. & Walls, H. M. Ocular complications of cryptococcal meningitis in patients with HIV: report of two cases and review of the literature. *J. Int. Assoc. Physicians AIDS Care* **11**, 283–288 (2012).
204. Neo, W. L., Durisala, N. & Ho, E. C. Reversible hearing loss following cryptococcal meningitis: case study. *J. Laryngol. Otol.* **130**, 691–695 (2016).
205. Wang, H. C. et al. The prognosis of hearing impairment complicating HIV-negative cryptococcal meningitis. *Neurology* **65**, 320–322 (2005).
206. Holikatti, P. C. & Kar, N. Psychiatric manifestations in a patient with HIV-associated neurocognitive symptoms and cryptococcal meningitis. *Indian. J. Psychol. Med.* **34**, 381–382 (2012).
207. Lofgren, S. M. et al. The effect of sertraline on depression and associations with persistent depression in survivors of HIV-related cryptococcal meningitis. *Wellcome Open Res.* **6**, 45 (2021).
208. Carlson, R. D. et al. Predictors of neurocognitive outcomes on antiretroviral therapy after cryptococcal meningitis: a prospective cohort study. *Metab. Brain Dis.* **29**, 269–279 (2014).
209. Levin, A. E. et al. Outpatient cryptococcal antigen screening is associated with favorable baseline characteristics and improved survival in persons with cryptococcal meningitis in Uganda. *Clin. Infect. Dis.* **76**, e759–e765 (2023).
210. Meya, D. B. et al. Reflexive laboratory-based cryptococcal antigen screening and preemptive fluconazole therapy for cryptococcal antigenemia in HIV-infected individuals with CD4 <100 cells/ μ L: a stepped-wedge, cluster-randomized trial. *J. Acquir. Immune Defic. Syndr.* **80**, 182–189 (2019).
211. Enock, K. et al. Evaluation of the initial 12 months of a routine cryptococcal antigen screening program in reduction of HIV-associated cryptococcal meningitis in Uganda. *BMC Health Serv. Res.* **22**, 301 (2022).
212. Lawrence, D. S. et al. Decision making in a clinical trial for a life-threatening illness: therapeutic expectation, not misconception. *Soc. Sci. Med.* **305**, 115082 (2022).
213. Link, A. et al. Delays in cryptococcal meningitis diagnosis and care: a mixed methods study in rural Uganda. *Ann. Glob. Health* **88**, 22 (2022).
214. Yaich, S. et al. Early onset of paucisymptomatic cryptococcal meningitis in a kidney transplant patient: a case report and review of the literature. *Transpl. Proc.* **43**, 663–665 (2011).
215. Bosnić, D. et al. Cryptococcal meningitis as a diagnostic problem in a patient with SLE – case report [Croatian]. *Lijec. Vjesn.* **130**, 136–140 (2008).
216. Jongwutiwes, U., Sungkanuparph, S. & Kiertiburanakul, S. Comparison of clinical features and survival between cryptococcosis in human immunodeficiency virus (HIV)-positive and HIV-negative patients. *Jpn. J. Infect. Dis.* **61**, 111–115 (2008).
217. Lin, T. Y. et al. Cryptococcal disease in patients with or without human immunodeficiency virus: clinical presentation and monitoring of serum cryptococcal antigen titers. *J. Microbiol. Immunol. Infect.* **42**, 220–226 (2009).
218. Srishyla, D. et al. Determinants of cryptococcal antigen (CrAg) screening uptake in Kampala, Uganda: an assessment of health center characteristics. *Med Mycol.* **60**, myac013 (2022).
219. Namuju, O. C. et al. Adherence of health workers to guidelines for screening and management of cryptococcal meningitis in Uganda. *PLoS ONE* **18**, e0284165 (2023).
220. Wake, R. M., Molloy, S. F., Jarvis, J. N., Harrison, T. S. & Govender, N. P. Cryptococcal antigenemia in advanced human immunodeficiency virus disease: pathophysiology, epidemiology, and clinical implications. *Clin. Infect. Dis.* **76**, 764–770 (2023).
221. Mpoza, E. et al. Cryptococcal antigenemia in human immunodeficiency virus antiretroviral therapy-experienced Ugandans with virologic failure. *Clin. Infect. Dis.* **71**, 1726–1731 (2020).
222. Boulware, D. R. et al. Oral lipid nanocrystal amphotericin B for cryptococcal meningitis: a randomized clinical trial. *Clin. Infect. Dis.* <https://doi.org/10.1093/cid/ciad440> (2023).
223. Ngan, N. T. T. et al. An open label randomized controlled trial of tamoxifen combined with amphotericin B and fluconazole for cryptococcal meningitis. *Elife* **10**, e68929 (2021).
224. Rhein, J. et al. Adjunctive sertraline for HIV-associated cryptococcal meningitis: a randomised, placebo-controlled, double-blind phase 3 trial. *Lancet Infect. Dis.* **19**, 843–851 (2019).
225. Shaw, K. J. et al. In vitro and in vivo evaluation of APX001A/APX001 and other Gwt1 inhibitors against *Cryptococcus*. *Antimicrob. Agents Chemother.* **62**, e00523-18 (2018).
226. Wiederhold, N. P. et al. Fungal-specific Cyp51 inhibitor VT-1598 demonstrates in vitro activity against *Candida* and *Cryptococcus* species, endemic fungi, including *Coccidioides* species, *Aspergillus* species and *Rhizopus arrizus*. *J. Antimicrob. Chemother.* **73**, 404–408 (2018).
227. Gerlach, E. S. et al. ATI-2307 exhibits equivalent antifungal activity in *Cryptococcus neoformans* clinical isolates with high and low fluconazole IC₅₀. *Front. Cell Infect. Microbiol.* **11**, 695240 (2021).
228. Guo, X. et al. Sterol sponge mechanism is conserved for glycosylated polyene macrolides. *ACS Cent. Sci.* **7**, 781–791 (2021).

229. World Health Organization. WHO fungal priority pathogens list to guide research, development and public health action. *World Health Organization* <https://www.who.int/publications/i/item/9789240060241> (2022).
230. Ending Cryptococcal Meningitis Deaths by 2030 – Strategic Framework. *Drugs for Neglected Diseases Initiative* <https://dndi.org/wp-content/uploads/2021/05/EndCryptococcalMeningitisDeaths2030-StrategicFramework-EN-2021.pdf> (2021).
231. Faini, D. et al. Laboratory-reflex cryptococcal antigen screening is associated with a survival benefit in Tanzania. *J. Acquir. Immune Defic. Syndr.* **80**, 205–213 (2019).
232. Nalintya, E. et al. A prospective evaluation of a multisite cryptococcal screening and treatment program in HIV clinics in Uganda. *J. Acquir. Immune Defic. Syndr.* **78**, 231–238 (2018).
233. Rolfes, M. A. et al. Cerebrospinal fluid culture positivity and clinical outcomes after amphotericin-based induction therapy for cryptococcal meningitis. *Open Forum Infect. Dis.* **2**, ofv157 (2015).
234. Grant, P. M. et al. Risk factor analyses for immune reconstitution inflammatory syndrome in a randomized study of early vs. deferred ART during an opportunistic infection. *PLoS ONE* **5**, e11416 (2010).
235. Bicanic, T. et al. Immune reconstitution inflammatory syndrome in HIV-associated cryptococcal meningitis: a prospective study. *J. Acquir. Immune Defic. Syndr.* **51**, 130–134 (2009).
236. Meza, D. B. et al. Cellular immune activation in cerebrospinal fluid from Ugandans with cryptococcal meningitis and immune reconstitution inflammatory syndrome. *J. Infect. Dis.* **211**, 1597–1606 (2015).

Acknowledgements

L.T. was supported by the Fogarty International Center of the National Institutes of Health under grant D43TW009345 awarded to the Northern Pacific Global Health Fellows Program.

J.K. and J.G. are supported by the Fogarty International Center and National Institute of Neurologic Disorders and Stroke (R01NS086312).

Author contributions

Introduction (L.T.); Epidemiology (L.T. and R.R.); Mechanisms/pathophysiology (L.T., J.K., K.S. and D.B.M.); Diagnosis, screening and prevention (L.T., R.R. and R.M.W.); Management (L.T., D.S.L., J.E., D.B.M., J.G. and M.A.); Quality of life (L.T. and M.A.); Outlook (L.T., D.R.B. and D.B.M.); all authors researched data for this article, discussed content and made revisions.

Competing interests

The authors declare no competing interests.

Additional information

Peer review information *Nature Reviews Disease Primers* thanks Nelesh Govender; William G. Powderly, who co-reviewed with Adriana Rauseo Acevedo; and the other, anonymous, reviewer(s) for their contribution to the peer review of this work.

Publisher's note Springer Nature remains neutral with regard to jurisdictional claims in published maps and institutional affiliations.

Springer Nature or its licensor (e.g. a society or other partner) holds exclusive rights to this article under a publishing agreement with the author(s) or other rightsholder(s); author self-archiving of the accepted manuscript version of this article is solely governed by the terms of such publishing agreement and applicable law.

© Springer Nature Limited 2023